CASE REPORT
(CC BY-SA)

UDC: 616.12-008.318-089.87
DOI: https://doi.org/10.2298/VSP260726061V

Catheter ablation of left ventricular outflow tract premature ventricular complexes in a patient with mechanical aortic and mitral valves

Kateterska ablacija komorskih ekstrasistola iz izlaznog trakta leve komore kod bolesnika sa mehaničkim aortnim i mitralnim zaliscima

Mihailo Vukmirović, Blagoje Babić

Clinical Center of Montenegro, Cardiology Department, Podgorica, Montenegro;
University of Montenegro, Medical Faculty, Podgorica, Montenegro

Abstract

Background. Catheter ablation of premature ventricular complexes (PVCs) originating from the left ventricular outflow tract (LVOT) is highly challenging in patients with dual prosthetic mechanical cardiac valves due to restricted ventricular access and the high risk of valvular damage. We report a case of successful catheter ablation of symptomatic, frequent PVCs from LVOT in a patient with mechanical aortic and mitral valves. **Case Report.** A 39-year-old man with previous mechanical aortic and mitral valve replacements presented with symptomatic, frequent PVCs in a bigeminal pattern refractory to medical therapy. Baseline electrocardiography suggested an LVOT origin. Given the double mechanical valves, standard retrograde or transseptal approaches into the left ventricle were precluded. Instead, electroanatomical mapping was safely restricted to the aortic root, superior to the mechanical aortic valve. Intracardiac echocardiography (ICE) was used throughout the procedure for continuous visualization of cardiac structures and precise catheter positioning. Applying radiofrequency energy within the right coronary sinus of Valsalva immediately suppressed the PVCs. Post-procedural ICE ruled out pericardial effusion as well as mechanical valvular interference. At the 12-month clinical follow-up, the patient remained entirely free of PVC recurrence. **Conclusion.** This case demonstrates that catheter ablation of PVCs from LVOT is feasible and safe in patients with mechanical aortic and mitral valves using a supravalvular approach, strictly guided by ICE.

Keywords:
ablation, techniques; arrhythmias, cardiac; echocardiography; heart valve prosthesis; pre-excitation syndromes.

Apstrakt

Uvod. Kateterska ablacija prevremenih komorskih ekstrasistola (*premature ventricular complexes* – PVCs), koje potiču iz izlaznog trakta leve komore (*left ventricular outflow tract* – LVOT), predstavlja veliki izazov kod bolesnika sa dve mehaničke proteze srčanih zalistaka zbog ograničenog pristupa srčanim komorama i visokog rizika od oštećenja zalistaka. Prikazujemo slučaj uspešne kateterske ablacije simptomatskih, učestalih PVCs iz LVOT kod bolesnika sa mehaničkim aortnim i mitralnim zaliscima. **Prikaz bolesnika.** Muškarac star 39 godina, sa prethodno ugrađenim mehaničkim aortnim i mitralnim zaliscima, javio se zbog simptomatskih, učestalih komorskih ekstrasistola po bigeminijskom obrascu, rezistentnih na medikamentnu terapiju. Početni elektrokardiogram ukazivao je na poreklo iz LVOT. S obzirom na dva mehanička zaliska, standardni retrogradni ili transseptalni pristupi levoj komori bili su onemogućeni. Umesto toga, elektroanatomsko mapiranje je bezbedno ograničeno na koren aorte, iznad mehaničkog aortnog zaliska. Intrakardijalna ehokardiografija (*intracardiac echocardiography* – ICE) korišćena je tokom cele procedure radi kontinuirane vizualizacije srčanih struktura i preciznog pozicioniranja katetera. Primena radiofrekventne energije unutar desnog koronarnog sinusa Valsalve dovela je do momentalne supresije PVCs. Postproceduralnom ICE isključen je perikardni izliv kao i poremećaji u radu mehaničkih zalistaka. Tokom perioda praćenja od 12 meseci, bolesnik je bio u potpunosti bez recidiva PVCs. **Zaključak.** Ovaj slučaj pokazuje da je kateterska ablacija PVCs iz LVOT izvodljiva i bezbedna kod bolesnika sa mehaničkim aortnim i mitralnim zaliscima korišćenjem supravalvularnog pristupa, strogo vođenog ICE-om.

Ključne reči:
ablacija, tehnike; srce, poremećaji ritma; ehokardiografija; zalisci srca, veštački; preeksitacijski sindromi.

Correspondence to: Mihailo Vukmirović, Clinical Center of Montenegro, Cardiology Department, Kruševac bb, 81 000 Podgorica, Montenegro. E-mail: mihailovukmirovic@t-com.me

Introduction

Premature ventricular complexes (PVCs) are common clinical arrhythmias that can become highly symptomatic or lead to tachycardia-induced cardiomyopathy when frequent. In these scenarios, catheter ablation serves as a highly effective, Class I recommended therapeutic strategy [1, 2].

Catheter ablation of PVCs arising from the left ventricular outflow tract (LVOT) requires precise electrocardiographic interpretation, identification of the earliest intracardiac activation, and close awareness of adjacent anatomical structures. Successful ablation in this region relies heavily on accurate localization of the arrhythmogenic focus and a meticulous mapping strategy to avoid injuring nearby critical structures, particularly the coronary arteries and the valvular apparatus [3].

The presence of mechanical prosthetic valves exponentially increases the complexity of these procedures. A mechanical mitral valve typically precludes standard transseptal access to the left ventricle, while a mechanical aortic valve prevents traditional retrograde transaortic crossing due to the high risks of catheter entrapment, valvular dysfunction, and thromboembolic events. Consequently, data regarding catheter ablation of LVOT-PVCs in patients with mechanical aortic and mitral valves remain extremely limited, though emerging studies suggest that such procedures are feasible with careful planning and advanced imaging modalities [4–6].

We report a case of successful catheter ablation of symptomatic, frequent LVOT-PVCs in a patient with dual mechanical valves—aortic and mitral. The arrhythmogenic focus was successfully mapped and ablated within the right coronary sinus of Valsalva entirely above the mechanical aortic valve, guided by a combination of fluoroscopy, electroanatomical mapping, and intracardiac echocardiography (ICE).

Case report

A 39-year-old man with a history of mechanical aortic and mitral valve replacements was referred for catheter ablation due to symptomatic ventricular ectopy and worsening heart failure despite optimal medical therapy. Baseline 12-lead electrocardiography (ECG) demonstrated sinus rhythm with a high burden of frequent PVCs presenting in a bigeminal pattern. The PVCs morphology was highly suggestive of an LVOT origin (Figure 1).

The procedure was performed under the guidance of fluoroscopy, three-dimensional electroanatomical mapping, and ICE (Figures 2, 3, and 4). Venous access was obtained *via* bilateral femoral vein punctures. A decapolar catheter was advanced into the coronary sinus for reference. Throughout the procedure, ICE was utilized for the direct, continuous visualization of intracardiac structures, monitoring catheter-valve proximity, and ruling out acute complications. Arterial access was achieved *via* the right femoral artery, and a radiofrequency ablation catheter was advanced through a long sheath.

Catheter manipulation was performed carefully in the aortic root region to avoid any interaction with the mechanical aortic valve (Figure 2).

Three-dimensional electroanatomical mapping accurately delineated the aortic root anatomy and localized the site of successful ablation within the right sinus of Valsalva, superior to the mechanical aortic valve (Figure 3).

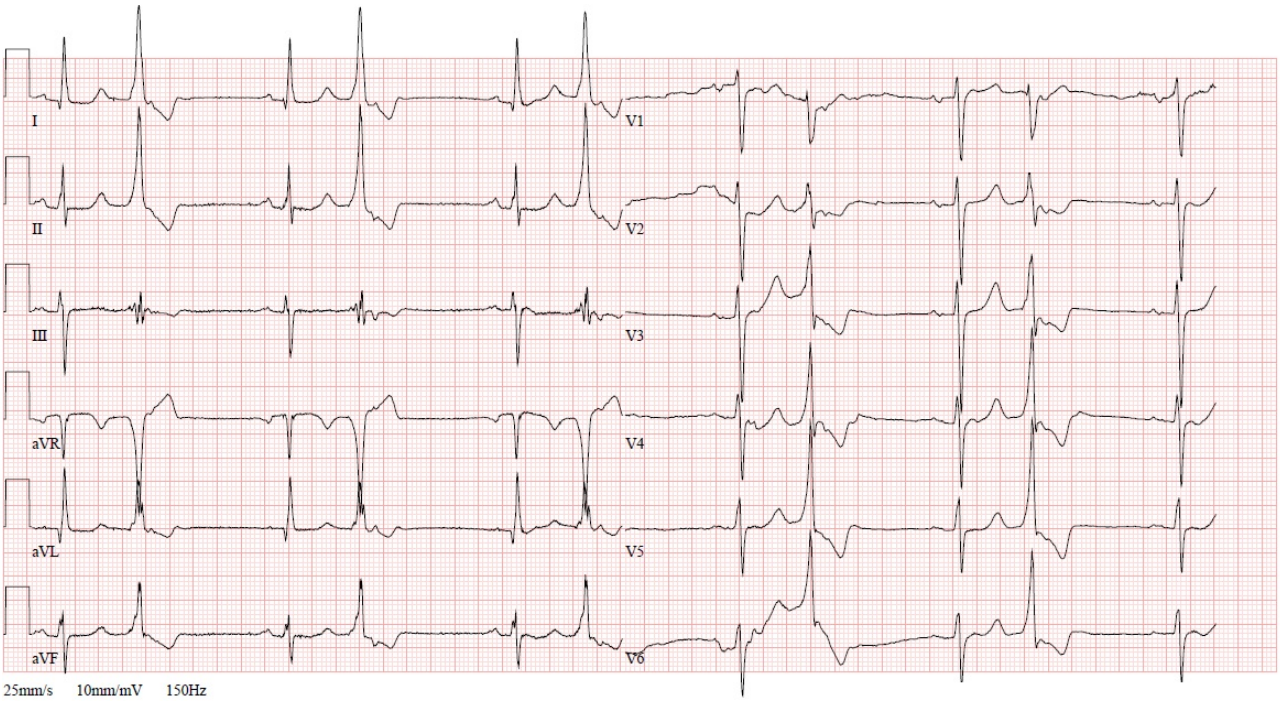

Fig. 1 – Baseline electrocardiogram showing ventricular bigeminy.

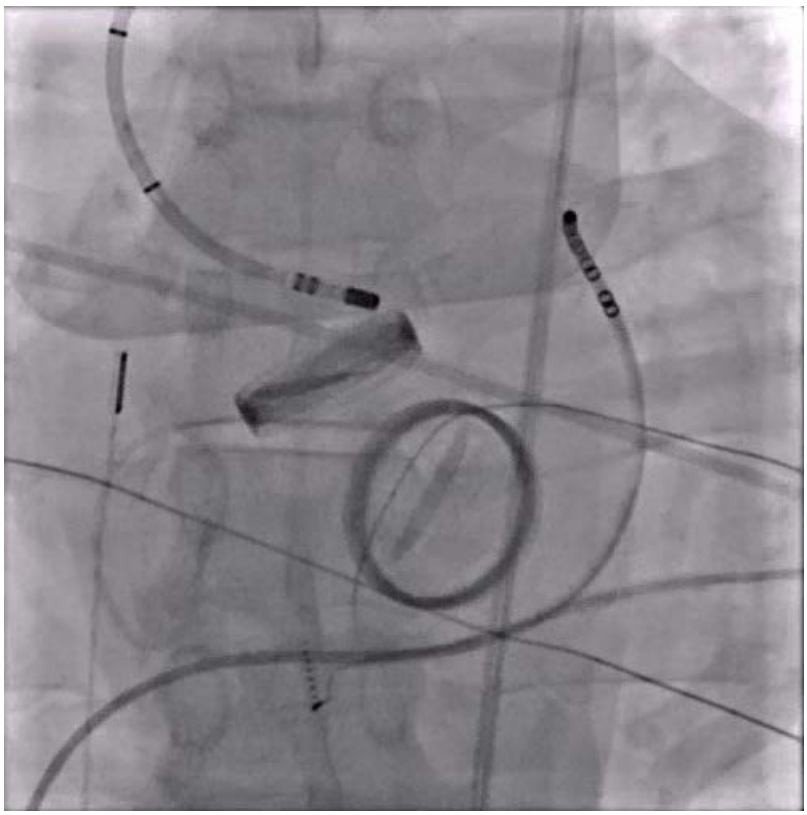

Fig. 2 – Left anterior oblique view of catheter position at the ablation site.

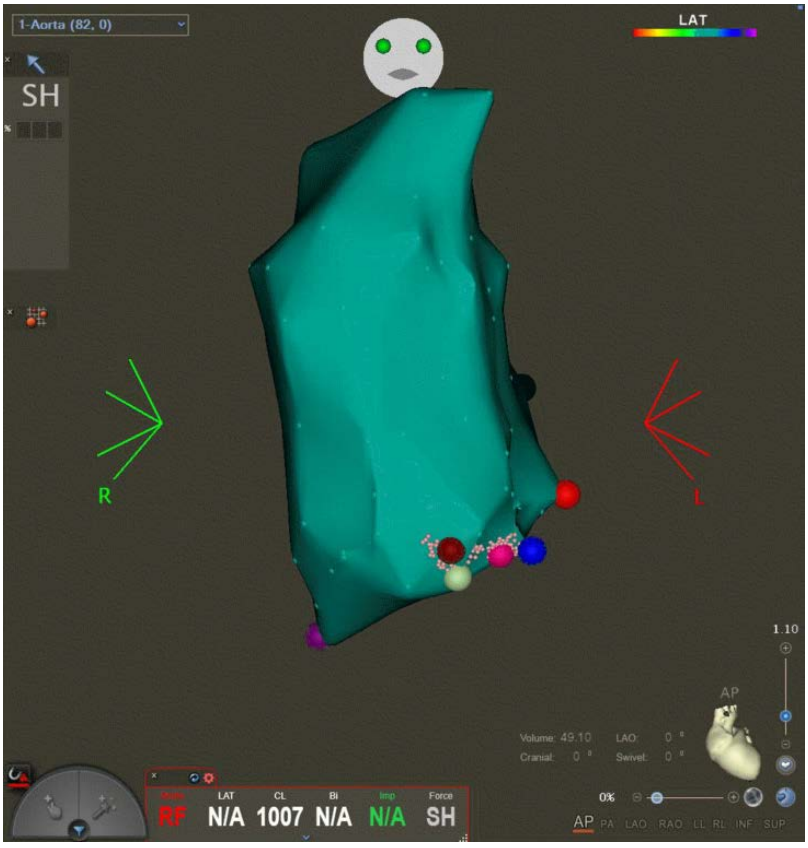

Fig. 3 – Three-dimensional (3D) electroanatomical map of the aortic root. Antero-posterior projection on the 3D mapping system. The dark purple dot represents the right coronary sinus, and the red dot represents the left coronary sinus. The remaining dots indicate mapping sites. Ablation was performed at the location marked by the blue dot.

ICE was utilized throughout the procedure for direct visualization of the mechanical aortic prosthesis and catheter positioning (Figure 4).

Given the dual mechanical valves, electroanatomical and activation mapping of the LVOT region was performed with extreme caution, strictly avoiding any catheter passage across the mechanical aortic valve disc. Mapping was focused within the aortic root. Intracardiac electrograms were recorded at the successful ablation site in the right sinus of Valsalva (Figure 5).

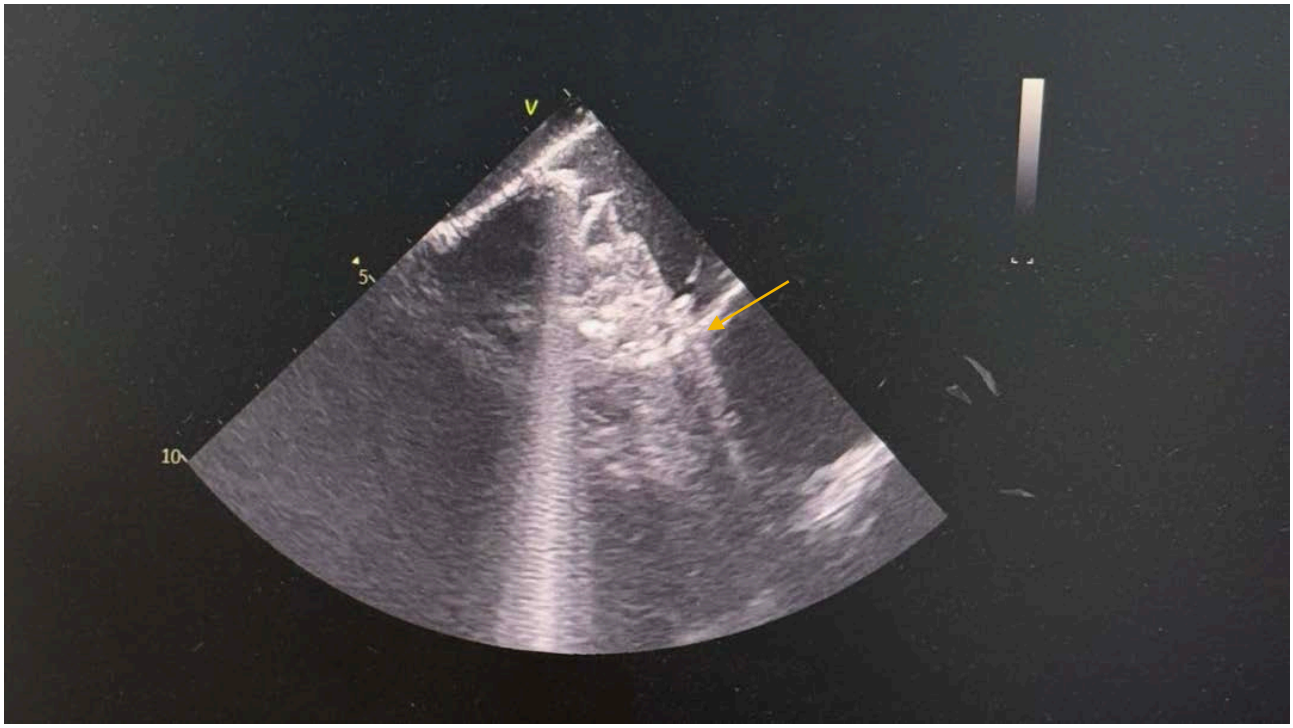

Fig. 4 – Intracardiac echocardiography during the procedure. The yellow arrow indicates the tip of the ablation catheter on intracardiac ultrasound.

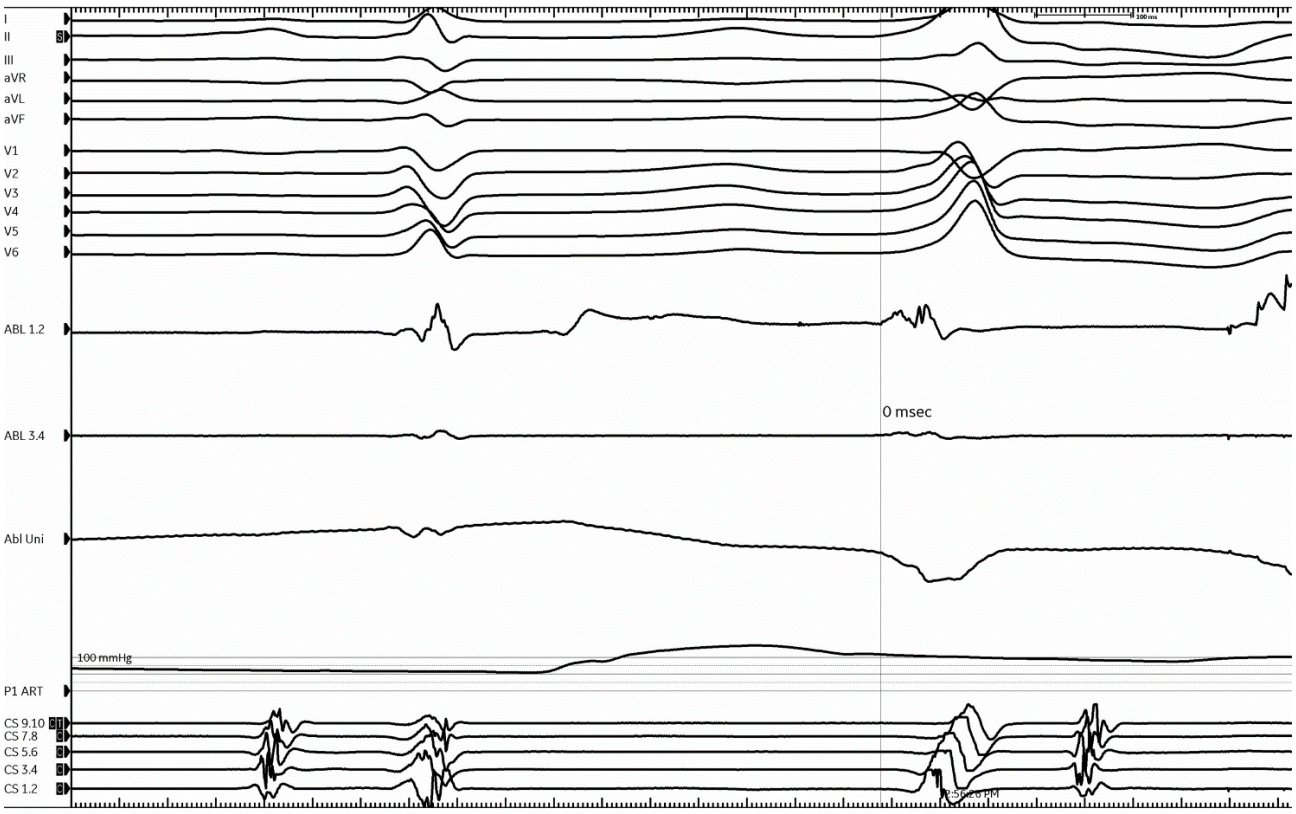

Fig. 5 – Intracardiac electrogram at the successful ablation site.

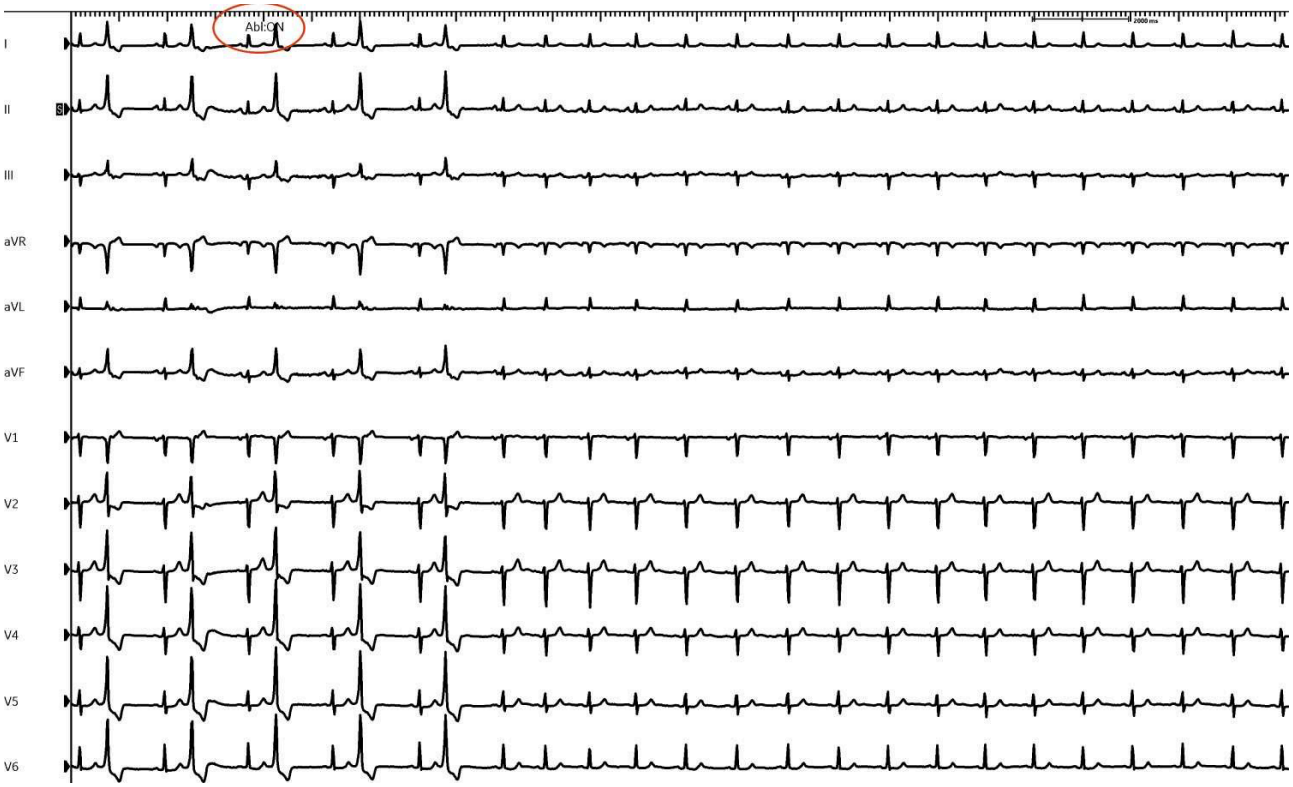

Fig. 6 – Suppression of ventricular ectopy during radiofrequency ablation. The red circle indicates the onset of ablation, i.e., the delivery of radiofrequency energy, immediately followed by the disappearance of premature ventricular complexes.

Although local intracardiac signals showed only modest activation prematurity, radiofrequency energy was delivered at this locus with a maximum power of 30 W. Intraprocedural rhythm tracings demonstrated prompt suppression of PVCs shortly after the initiation of radiofrequency energy delivery (Figure 6). Ventricular ectopy terminated immediately within the first few seconds of application, with a total radiofrequency delivery time of 197 seconds.

Fluoroscopic and electroanatomical imaging confirmed the precise position of the catheter tip within the right coronary sinus, safely clear of the mechanical aortic valve apparatus (Figure 2). Post-procedural ICE confirmed the absence of pericardial effusion or valvular interference. During the 12-month clinical follow-up, the patient remained entirely asymptomatic with no documented recurrence of PVCs.

Discussion

This case highlights the clinical feasibility and safety of catheter ablation for LVOT-PVCs in a patient with mechanical aortic and mitral valve replacements. The primary procedural challenges in this population are the absolute restriction of traditional access routes into the left ventricle and the catastrophic risks associated with catheter-prosthesis interaction.

In patients with standard anatomy, LVOT-PVCs are routinely approached *via* a retrograde transaortic route or a transseptal approach to map the subvalvular LVOT, the aortic cusps, and adjacent structures. Conversely, in patients with a double mechanical valve configuration, the mechanical mitral prosthesis precludes the transseptal approach, and retrograde transaortic crossing is strictly contraindicated because of the high risk of catheter entrapment, valvular disc immobilization, and thromboembolic stroke. Although published data on ventricular arrhythmia ablation with dual mechanical valves remain sparse, our findings align with limited reports showing that these procedures, though technically demanding, are achievable through meticulous strategic planning and advanced imaging modalities [4–6].

Ablation within the aortic root carries inherent risks due to its proximity to the coronary artery ostia and the mechanical valve apparatus. Traditionally, coronary angiography has been mandated to ensure a safe clearance from the coronary ostia during radiofrequency delivery. However, ICE has emerged as a transformative tool, providing high-resolution, real-time visualization of the aortic cusp anatomy, the coronary ostia, and precise catheter-tip stability [7, 8]. Hoffmayer et al. [7] demonstrated that aortic root ablations could be safely performed using a combination of ICE and electroanatomical mapping without routine coronary angiography, provided there is direct visual confirmation of the catheter tip relative to the coronary openings. Similarly, Al Asmar et al. [8] reported that experienced operators could successfully perform mapping and radiofrequency ablation within the sinuses of Valsalva under ICE guidance without supplementary angiography, with no immediate or 30-day adverse events. These data strongly support using ICE as the primary safety modality in anatomically sensitive aortic root procedures.

In our patient, ICE served as the critical safety cornerstone. It provided continuous monitoring of catheter position and stability within the aortic root, ensuring the catheter remained safely clear of the mechanical aortic valve discs. Furthermore, ICE allowed immediate, real-time exclusion of pericardial effusion or mechanical valvular interference after ablation. To further mitigate risks, radiofrequency energy was delivered cautiously using an irrigated-tip catheter at a moderate power of 30 W. The immediate termination of the PVCs during the initial seconds of radiofrequency delivery, the lack of acute recurrence during the intraprocedural waiting period, and the durable elimination of frequent ectopy at the 12-month follow-up collectively validate the safety and efficacy of this supravalvular strategy.

The principal teaching point of this case is that dual mechanical heart valves should not be considered an absolute contraindication for the ablation of LVOT-PVCs. When the arrhythmogenic focus lies supravalvularly within the sinuses of Valsalva, successful ablation can be safely achieved through careful pre-procedural planning, electroanatomical mapping, and rigorous intracardiac echocardiographic guidance.

Conclusion

Catheter ablation of LVOT-PVCs in patients with mechanical aortic and mitral valve replacements is technically demanding but clinically feasible. When the arrhythmogenic focus is situated supravalvularly, electroanatomical mapping within the aortic root enables successful localization and ablation while completely avoiding hazardous catheter passage across the prosthetic valve apparatus. In this complex anatomical setting, integrating intracardiac echocardiography provides critical real-time visualization of the coronary ostia and valve structures, significantly improving procedural safety and efficacy.

REFERENCES

1. *Zeppenfeld K, Tfelt-Hansen J, de Riva M, Winkel BG, Behr ER, Blom NA,* et al. 2022 ESC Guidelines for the management of patients with ventricular arrhythmias and the prevention of sudden cardiac death. Eur Heart J 2022; 43(40): 3997–4126. DOI: 10.1093/eurheartj/ehac262.
2. *Cronin EM, Bogun FM, Maury P, Peichl P, Chen M, Namboodiri N,* et al. 2019 HRS/EHRA/APHRS/LAHRS expert consensus statement on catheter ablation of ventricular arrhythmias. Heart Rhythm 2020; 17(1): e2–154. DOI: 10.1016/j.hrthm.2019.03.002.
3. *Enriquez A, Muser D, Markman TM, Garcia F.* Mapping and ablation of premature ventricular complexes: state of the art. JACC Clin Electrophysiol 2024; 10(6): 1206–22. DOI: 10.1016/j.jacep.2024.02.008.
4. *Rozen G, Elbaz-Greener G, Andria N, Heist EK, Ruskin JN, Wijeysundera HC,* et al. Ventricular arrhythmia ablation in the presence of mechanical valve: utilization and complications of catheter ablation for ventricular arrhythmia in patients with mechanical prosthetic valves. J Cardiovasc Electrophysiol 2021; 32(12): 3165–72. DOI: 10.1111/jce.15271.
5. *Khalil F, Toya T, Madhavan M, Badany M, Ahmad A, Kapa S,* et al. Characteristics and outcomes of ventricular tachycardia and premature ventricular contractions ablation in patients with prior mitral valve surgery. J Cardiovasc Electrophysiol 2022; 33(2): 274–83. DOI: 10.1111/jce.15331.
6. *Khalil F, Toya T, Ahmad A, Siontis KC, Mulpuru SK, Del-Carpio Munoz F,* et al. Ventricular arrhythmias in patients with prior aortic valve intervention: characteristics, ablation and outcomes. J Cardiovasc Electrophysiol 2023; 34(5): 1206–15. DOI: 10.1111/jce.15896.
7. *Hoffmayer KS, Dewland TA, Hsia HH, Badhwar N, Hsu JC, Scheinman MM,* et al. Safety of radiofrequency catheter ablation without coronary angiography in aortic cusp ventricular arrhythmias. Heart Rhythm 2014; 11(7): 1117–21. DOI: 10.1016/j.hrthm.2014.04.019.
8. *Al Asmar M, Houssari M, El-Tallawi KC, Feghali T, Refaat M, Khoury M,* et al. Safety of mapping in the sinus of valsalva region under intracardiac echocardiography guidance without angiography. Indian Pacing Electrophysiol J 2021; 21(3): 141–4. DOI: 10.1016/j.ipej.2021.02.003.

Received on July 26, 2026
Accepted on September 9, 2026
Online First November 2026