



The assessment of the stability of the corneal structure after LASIK correction of myopia by different optical zone diameters

Procena stabilnosti strukture rožnjače nakon korekcije kratkovidosti metodom LASIK sa različitim prečnicima optičke zone

Milorad Milivojević*, Vladimir Petrović*, Miroslav Vukosavljević*,
Ivan Marjanović‡§, Mirko Resan*

*Clinic for Ophthalmology, Military Medical Academy, Belgrade, Serbia; †Faculty of Medicine of the Military Medical Academy, University of Defence, Belgrade, Serbia;

‡Clinic for Ophthalmology, Clinical Center of Serbia, Belgrade, Serbia; §Faculty of Medicine, University of Belgrade, Belgrade, Serbia

Abstract

Background/Aim. Enlargement of optical zone (OZ) diameter during laser *in situ* keratomileusis (LASIK) correction of myopia postoperatively improves the optical outcome, however, it also leads to the increased stroma tissue consumption – progressive corneal thinning. The aim of this investigation was to present the possibility of safe OZ enlargement without impairing the structural stability of the cornea, while obtaining an improved optical outcome with LASIK treatment of short-sightedness. **Methods.** Preoperative assessment of the cornea structure and prediction of the ablated stroma tissue consumption was conducted in 37 patients (74 eyes) treated for short-sightedness by means of the LASIK method. With the eyes that, according to their cornea structure, had the capacity for OZ diameter enlargement of 0.5 mm, LASIK treatment was performed within the wider OZ diameter of 7.0 mm compared to the standard 6.5 mm. The following two groups were formed, depending on the diameter of the utilized OZ: the group I (the eyes treated with the OZ 6.5 mm, $n = 37$) and the group II (the eyes treated with the OZ 7.0 mm, $n = 37$). **Results.** No significant difference in the observed structural parameters of the cornea was detected between the groups of patients treated with different OZ diameters. The values of all the parameters were significantly below the threshold values for the development of postoperative ectasia. **Conclusion.** Diameter enlargement of the treated OZ, if there is a preoperative cornea capacity for such enlargement, will not impair the postoperative stability of the cornea structure, and will significantly improve the optical outcome.

Key words:
myopia; keratomileusis, laser in situ; ophthalmologic surgical procedures; cornea; treatment outcome.

Apstrakt

Uvod/Cilj. Proširenjem optičke zone (OZ) tokom korekcije kratkovidosti metodom *laser in situ keratomileusis* (LASIK) poboljšava se postoperativni ishod tretmana laserom, ali se istovremeno povećava potrošnja tkiva strome rožnjače – dolazi do progresije njenog istanjenja. Cilj rada bio je da se pokaže mogućnost bezbednog proširenja OZ bez narušavanja strukturne stabilnosti rožnjače, uz poboljšani ishod tretmana laserom nakon korekcije kratkovidosti. **Metode.** Preoperativno je sagledana struktura rožnjače i procenjen ablativni profil korekcije, na osnovu čega je predviđena postoperativna struktura rožnjače na očima 37 kratkovidih pacijenata (74 oka). Na osnovu sagledavanja strukturnih parametara procenjen je kapacitet strome rožnjače za proširenje tretirane OZ sa standardnih 6,5 mm na 7,0 mm OZ. U zavisnosti od prečnika OZ korišćene tokom lečenja formirane su dve grupe: grupa I (oči tretirane korišćenjem OZ 6,5 mm, $n = 37$) i grupa II (oči tretirane korišćenjem OZ 7,0 mm, $n = 37$). **Rezultati.** Analizom posmatranih strukturnih parametara uočeno je da su u obe posmatrane grupe njihove vrednosti bile značajno veće od graničnih koje su označene kao kritične za pojavu postoperativne ektazije nakon korekcije kratkovidosti metodom LASIK. **Zaključak.** Proširenjem prečnika tretirane OZ za 0,5 mm, ukoliko postoji odgovarajući kapacitet tkiva strome rožnjače, postoperativno se nakon korekcije kratkovidosti metodom LASIK ne narušava strukturna stabilnost rožnjače, a poboljšava se ishod laserske korekcije miopije.

Ključne reči:
miopija; keratomileusis, laser in situ; hirurgija, oftalmološka, procedure; rožnjača; lečenje, ishod.

Introduction

Excimer laser pulses are used for remodeling of the corneal stroma with the aim of refractive anomaly correction, with the tissue being removed by means of evaporation and therefore leading to corneal stroma remodeling and thinning. The quantity of the removed tissue is proportional to the size of the corrected diopter ametropia and to the radius of the treated optical zone (OZ). According to Munnerlyn et al.¹, for corrections up to -7.0 diopter sphere (Dsph) the following formula is used: the depth of the ablation (μm) is equal to the number of diopters multiplied by the square of the OZ diameter (mm) divided by three: $\text{Depth ab } (\mu\text{m}) = \text{Dsph} \times \text{OZ}^2 \text{ (mm)} / 3$.

Impairing the cornea structure beyond the critical values of the structural parameters (corneal pachymetry, corneal thickness progression and corneal volume reduction), will lead to the most severe complication of laser *in situ* keratomileusis (LASIK) treatment – corneal ectasia². Enlargement of the OZ diameter during LASIK correction of myopia will postoperatively improve the optical outcome, however it will also lead to the increased stroma tissue consumption – progressive corneal thinning.

The aim of this work was to present the possibility of safe OZ diameter enlargement without impairing the structural stability of the cornea, while obtaining an improved optical outcome with LASIK treatment of short-sightedness.

Methods

A prospective clinical study, conducted at the Military Medical Academy, Clinic for Ophthalmology (January 2010 – June 2012), included 37 patients treated for the existing ametropia by means of the LASIK method with a Wavelight Allegretto 400 Hz excimer laser. The study was approved by the Military Medical Academy Ethics Committee. The study included patients with myopia and myopic astigmatism. The total number of the eyes treated was 74.

The following two groups were formed, depending on the diameter of the utilized OZ during the treatment with the excimer laser: the group I (the eyes treated with the OZ 6.5 mm, $n = 37$); the group II (the eyes treated with the OZ 7.0 mm, $n = 37$).

The decision criteria for the selection of OZ diameter was based on evaluation and application of the excimer laser software for the expected postoperative thickness of the residual stromal bed (RSB) for each eye, and simulation of OZ treatment for 6.5 mm or 7.0 mm, so that the eye with greater postoperative thickness of the RSB was treated with the OZ 7.0 mm, and the eye

with lower RSB value, in the same patient, was treated with the OZ 6.5 mm which was larger than the scotopic pupile diameter.

Camera recording, using the Scheimpflug system, and measuring of the postoperative structural parameters: corneal pachymetry, corneal thickness progression and corneal volume reduction, were performed after six months.

The obtained data were analyzed and showed in the text and figures. The results were presented as means with standard deviations (SD). Throughout the study, Wilcoxon and Mann-Whitney *U*-test with a statistically significant cutoff of $p < 0.05$ were used to assess the statistical significance of parameters observed.

Results

The average patient's age was 32.34 years and the youngest treated patient was 21 year old. The highest value for myopia was 8.75 diopter sphere. The average value of corneal pachymetry in our patients was $545.86 \pm 33.94 \mu\text{m}$, ranging from $503 \mu\text{m}$ to $599 \mu\text{m}$, while the average value of the postoperative corneal pachymetry from the two observed groups was $492 \mu\text{m}$.

Postoperatively, the average value of corneal pachymetry for the group I, treated with the OZ 6.5 mm, was $491.55 \pm 48.24 \mu\text{m}$ (Figure 1) while in the group II, treated with the OZ 7.0 mm, $493.04 \pm 49.23 \mu\text{m}$ of the thinnest corneal part was registered.

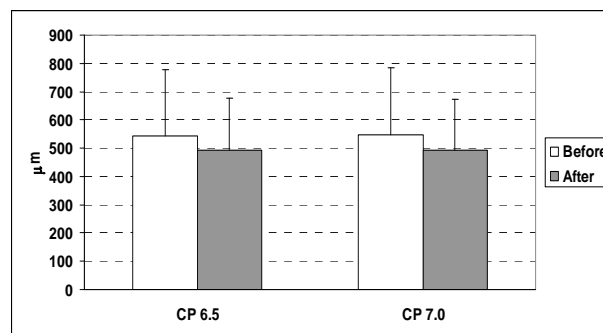


Fig. 1 – Corneal pachymetry (CP) changes in the patients after the laser *in situ* keratomileusis (LASIK) treatment in different optical zones – 6.5 mm : 7.0 mm.

When comparing the preoperative values of corneal pachymetry between the group I and the group II (Table 1), no significant differences were observed. So, an equivalence of corneal pachymetry was observed between the groups before the treatment (Mann-Whitney; $Z = 0.63$; $p = 0.52$).

Moreover, the comparison of the total postoperative values of the thinnest part of corneal pachymetry between the

Table 1
Statistical analysis of corneal pachymetry (CP) values before and after the laser *in situ* keratomileusis (LASIK) treatment in different optical zones – 6.5 mm : 7.0 mm

Groups (type of comparison)	Z value	p
CP 6.5 (before : after)	0.34	0.73
CP 7.0 (before : after)	0.45	0.65
CP 6.5: CP 7.0 (before)	0.63	0.52
CP 6.5: CP 7.0 (after)	0.32	0.75
% of before-after change (CP 6.5: CP 7.0)	0.09	0.92

groups showed no significant differences (Mann-Whitney; $Z = 0.32$; $p = 0.74$).

The comparison of the decreased corneal pachymetry values by OZ ablation in the diameter of 6.5 mm and the wider diameter of 7.0 mm, showed no significant difference in the change of corneal pachymetry at different ablation parameters (Mann-Whitney; $Z = 0.09$; $p = 0.92$); (Table 1).

The values (Figure 2) and comparison of corneal volume consumption at the OZ ablation diameter of 6.5 mm, when compared to the OZ ablation diameter of 7.0 mm (Table 2), showed no significant differences in stroma consumption (Mann-Whitney; $Z = 0.60$; $p = 0.54$).

The values of both groups (Figure 3) and comparison of the corneal thickness progression after the LASIK procedure between the group I and the group II showed no significant difference as well (Table 3). It can be concluded that the enlargement of the OZ radius of 0.5 mm does not make a significant difference to the postoperative increase of the corneal thickness progression in central 6.5 mm of measured diameter of cornea.

Discussion

The diameter enlargement of 0.5 mm for the treated OZ, starting with the standard 6.5 up to 7.0 mm, increases the ablation depth and the volume consumption of the stromal tissue – progressive corneal thinning occurs during the LASIK procedure.

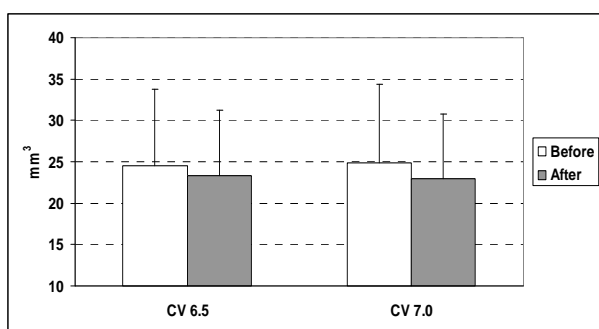


Fig. 2 – Corneal Volume (CV) changes in patients after the laser *in situ* keratomileusis (LASIK) treatment in different optical zones – 6.5 mm : 7.0 mm.

re. The criteria for the selection of patients – eyes for the wider diameter of the treated cornea were based on the references from Binder and Trattler³ and Randleman et al.⁴, as well as the predictions on the postoperative structure of cornea based on the software program for Wave Light Allegretto Q 400 laser, and our own previous research results^{5,6}. We monitored and analyzed the cornea structural stability parameters, such as the value of corneal pachymetry, corneal volume and corneal thickness progression. Other parameters such as age as well as the highest myopic value for myopia we consider as parameters of lower level of importance. We believe that these parameters have no relevant importance for the development of ectasia as much as those structural parameters that we followed in this study.

Corneal pachymetry is perceived as the basic numerical parameter for the assessment of the postoperative stability of the cornea after the LASIK treatment and for the comparison between the observed groups. Postoperatively, the average value of corneal pachymetry in our study was 491.55 μm for the group treated with the OZ 6.5 mm, while for the group treated with the OZ 7.0 mm, the average value of corneal pachymetry was 493.04 μm . According to the empiric conclusions of Ambrósio et al.⁷, the threshold value of corneal pachymetry for the development of the ectatic process is $424 \pm 50.93 \mu\text{m}$ which is significantly lower than the values measured in both groups after the LASIK treatment.

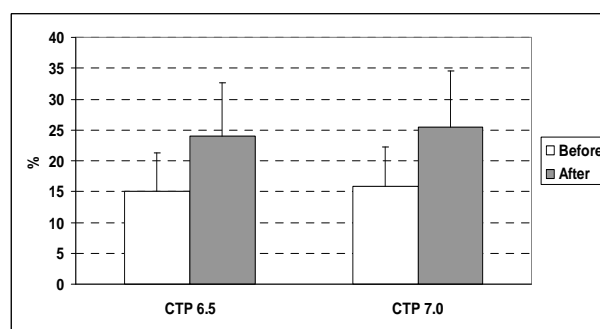


Fig. 3 – Corneal thickness progression (CTP) changes in the patients after the laser *in situ* keratomileusis (LASIK) treatment in different optical zones – 6.5 mm : 7.0 mm.

Table 2
Statistical analysis of corneal volume (CV) values before and after the laser *in situ* keratomileusis (LASIK) treatment

Groups (type of comparison)	Z value	p
CV 6.5 (before : after)	0.28	0.79
CV 7.0 (before : after)	0.38	0.69
CV 6.5: CV 7.0 (before)	0.59	0.55
CV 6.5: CV 7.0 (after)	0.71	0.48
% of before-after change (CV 6.5: CV 7.0)	0.60	0.54

Table 3
Statistical analysis of corneal thickness progression (CTP) values before and after the laser *in situ* keratomileusis (LASIK) treatment

Groups (type of comparison)	Z value	p
CTP 6.5 (before : after)	4.03	< 0.001*
CTP 7.0 (before : after)	3.98	< 0.001*
CTP 6.5: CTP 7.0 (before)	0.27	0.79
CTP 6.5: CTP 7.0 (after)	0.31	0.75
% of before-after change (CTP 6.5: CTP 7.0)	0.10	0.88

*statistically significant difference ($p < 0.05$).

The lower limit of the residual corneal volume of $22.4 \pm 2.0 \text{ mm}^3$, within the measurement radius of the central 7.0 mm corneal area, was based on the statement of the same author – Ambrósio et al.⁷, who defined the parameter (Corneal Thickness Spatial Profile–CTSP) as the critical value for the development of the ectatic process. The average value of the postoperative corneal volume in our study, determined in the group treated with the OZ 6.5 mm was $23.33 \pm 1.30 \text{ mm}^3$, and in the group treated with the OZ 7.0 mm $22.98 \pm 3.37 \text{ mm}^3$. This is significantly beyond the above mentioned limit of 22.4 mm^3 , which is significant for the development of the ectatic process.

Corneal thickness progression after the LASIK treatment, with the value of 31.4% for the optical zone radius of 6.0 mm, was marked as the critical value for the development of the postoperative ectasia, based on the statement of Ambrósio et al.⁷. Throughout the research, it was determined that the average postoperative value of corneal thickness progression was $24.02 \pm 7.04\%$, for the group treated with the OZ radius of 6.5 mm, and for the group treated with the OZ 7.0 mm, the corresponding value was $25.37 \pm 8.70\%$ (which is, in case of both observed groups, significantly below the above mentioned critical value of 31.4 %).

In some of their earlier studies, our Clinic's authors^{5, 6} determined the average consumption of $0.43 \pm 0.18 \text{ mm}^3$ in the group treated with the OZ 6.5 mm *per* one diopter correction, and in the group treated with the OZ 7.0 mm, the ablated volume was $0.61 \pm 0.31 \text{ mm}^3$ *per* one diopter correction of myopia.

Throughout our research, we were guided by the statements of Ambrósio et al.⁷, regarding the critical value of the postoperative volume of 22.41 mm^3 within the measurement diameter of 7.0 mm, as the critical value for the changes in the corneal structure. In no case was it determined that the measurement of the residual corneal volume with Oculyzer device, six months after the LASIK procedure, exceeded this threshold value.

The comparison of the corneal thickness progression after the LASIK correction between the groups treated with the OZ radius of 6.5 mm and the group treated with the OZ radius of 7.0 mm, showed no significant difference as well.

Having in mind a relatively short period of follow-up (only 2 years) the possibility for the appearance of postope-

rative ectasia cannot be absolutely excluded but it can be concluded that the enlargement of the OZ radius of 0.5 mm does not make a significant difference to the postoperative increase of the corneal thickness progression.

As recommended by the American Academy of Ophthalmology, and based on the available literature data, throughout our clinical work we were guided by the reference to the minimal value of the preoperative corneal pachymetry of $500 \mu\text{m}$ ^{8,9}, while the average value of corneal pachymetry in our patients was $545.86 \pm 33.94 \mu\text{m}$, ranging from $503 \mu\text{m}$ to $599 \mu\text{m}$. Twa et al.² in the abovementioned research on the characteristics of corneal ectasia after myopic LASIK treatment states that the average corneal pachymetry within the group of patients who developed ectasia was $512 \mu\text{m}$ (in the range of $498\text{--}530 \mu\text{m}$), and that the limit value of $\leq 400 \mu\text{m}$ is considered to be a significant value of the postoperative corneal pachymetry for the development of ectasia. In our patients the average value of postoperative corneal pachymetry observed groups was $492 \mu\text{m}$, which indicates that the preoperative corneal pachymetry values in our study were significantly higher than this value.

Preoperative assessment of the cornea structure, based on Scheimpflug camera recording and processing by means of the Oculyzer device software system, and the assessment of the ablation profile with the Allegretto Wave Light Q 400 laser software system, adhering to the corneal topography criteria^{5, 10}, provides a reliable estimate of the postoperative cornea structure. When structural characteristics, together with the ablation profile assessment and the stromal tissue consumption, during LASIK correction of myopia, indicate the stable postoperative cornea structure, diameter enlargement of the treated optical zone improves the optical outcome of LASIK treatment.

Conclusion

Our experience indicates that, in patients with the adequate capacity of corneal stroma, the diameter enlargement of the optical zone from the standard 6.5 mm to 7.0 mm does not impair the cornea structural stability parameters after the LASIK treatment and after six months of monitoring, while the optical outcome is improved, and that, therefore, it is advisable to enlarge the diameter of the optical zone when there are potential opportunities for such a procedure.

REFERENCES

1. Munnerlyn C, Koons S, Marshall J. Photorefractive keratectomy: A technique for laser refractive surgery. *J Cataract Refract Surg* 1988; 14(1): 46-52.
2. Twa MD, Nichols JJ, Joslin CE, Kollbaum PS, Edrington TB, Bullimore MA, et al. Characteristics of corneal ectasia after LASIK for myopia. *Cornea* 2004; 23(5): 447-57.
3. Binder PS, Trattler WB. Evaluation of a risk factor scoring system for corneal ectasia after LASIK in eyes with normal m topography. *J Refract Surg* 2010; 26(4): 241-50.
4. Randleman JB, Woodward M, Lynn MJ, Stulting RD. Risk assessment for ectasia after corneal refractive surgery. *Ophthalmology* 2008; 115(1): 37-50.
5. Vukosavljević M, Milivojević M, Resan M, Cerović V. Laser in situ keratomileusis (LASIK) for correction of myopia and hypermetropia-our one year experience. *Vojnosanit Pregl* 2009; 66(12): 979-84. (Serbian)
6. Resan M, Vukosavljević M, Milivojević M. Photorefractive keratectomy (PRK) for correction of myopia-our one year experience. *Vojnosanit Pregl* 2012; 69(10): 852-7. (Serbian)

7. *Ambrósio R Jr, Alonso RS, Luç A, Coca Velarde LG.* Corneal-thickness spatial profile and corneal-volume distribution: tomographic indices to detect keratoconus. *J Cataract Refract Surg* 2006; 32(11): 1851–9.
8. *American Academy of Ophthalmology.* Refractive surgery. The Role of the FDA in Refractive Surgery. San Francisco: Eye M.D. Association; 2009.
9. *Kim TH, Lee D, Lee HI.* The safety of 250 microm residual stromal bed in preventing keratectasia after laser in situ keratomileusis (LASIK). *J Korean Med Sci* 2007; 22(1): 142–5.
10. *Binder PS.* Risk factors for ectasia after LASIK. *J Cataract Refract Surg* 2008; 34(12): 2010–1.

Received on June 27, 2014.
Revised on April 22, 2015.
Accepted on April 24, 2015.
Online First May, 2015.