



Unusual case of mixed form of femoroacetabular impingement combined with nonspecific synovitis of the hip joint in a young adult – A case report

Neobičan slučaj mešovite forme femoroacetabularnog impingementa kombinovanog sa nespecifičnim sinovitisom zgloba kuka kod mlade osobe

Marko Mladenović*, Ivan Micić*†, Zoran Andjelković‡, Desimir Mladenović*†, Predrag Stojiljković*†

*Ortopedics and Traumatology Clinic, Clinical Center Niš, Niš, Serbia; †Faculty of Medicine, University of Niš, Niš, Serbia; ‡Department of Orthopedics and Traumatology, General Hospital Leskovac, Leskovac, Serbia

Abstract

Introduction. Minimal bone changes in the acetabulum and/or proximal femur, through mechanism known as femoroacetabular impingement, during flexion, adduction and internal rotation lead to early contact between femoral head-neck junction and acetabular brim, in anterosuperior region. Each additional pathological substrate which further decreases specified clearance provokes earlier onset of femoroacetabular impingement symptoms. **Case report.** We presented a 20-year-old male patient with groin pain, limping, positive impingement test, radiological signs of mixed form of femoroacetabular impingement and unrecognized chronic hypertrophic synovitis with earlier development of clinical hip symptoms than it has been expected. Open surgery of the left hip was done. Two years after the surgery, patient was asymptomatic, painless, and free of motion, with stable x-rays. **Conclusion.** Hypertrophic synovial tissue further reduces the distance between the femoral head-neck junction and the acetabulum, leading to the earlier onset of femoroacetabular impingement symptoms. Surgical treatment is the method of choice.

Key words:

femoracetabular impingement; synovitis; hip joint; orthopedic procedures; treatment outcome.

Apstrakt

Uvod. Minimalne koštane promene na acetabulumu i/ili proksimalnom femuru, mehanizmom poznatim kao femoroacetabularni impingement u toku fleksije, addukcije i unutrašnje rotacije vode u raniji kontakt između spoja femoralne glave i vrata sa ivicom acetabuluma u anterosuperiornjoj regiji. Svaki dodatni patološki supstrat koji dalje smanjuje rastojanje između ivice acetabuluma i vrata femura provocira raniju pojavu simptoma femoroacetabularnog impingementa. **Prikaz bolesnika.** Prikazali smo bolesnika, starog 20 godina, sa bolom u preponi, hramanjem, pozitivnim testom impingementa, radiografskim snimcima mešovite forme femoroacetabularnog impingementa i neprepoznatim hroničnim hipertrofičnim sinovitisom kuka. Urađena je otvorena hirurška procedura levog kuka. Dve godine nakon operacije, bolesnik je bez tegoba, punog obima pokreta, sa nepromenjenim radiografskim nalazom zgloba kuka. **Zaključak.** Hipertrofični sinovitis kuka dodatno smanjuje rastojanje između spoja femoralne glave i vrata i acetabuluma i dovodi do ranije pojave simptoma femoroacetabularnog impingementa. Hirurško lečenje je metoda izbora.

Ključne reči:

femoroacetabularni sudar; sinovitis; kuk, zglob; ortopedске procedure; lečenje, ishod.

Introduction

Acetabular labrum damage leads to loss of its function, early appearance of groin pain, loss of hip function and early hip osteoarthritis development^{1,2}. Numerous pathomechanism have been proposed to explain the labrum damage, in-

cluding the femoroacetabular impingement (FAI)^{3,4}. Minimal bone changes of the acetabulum and/or femoral head, reduce the distance between them, leading to premature contact-impact of the femoral head-neck junction on the edge of the acetabulum, damaging labrum and labrum adjacent cartilage, which are early signs of hip arthritis⁵⁻⁸. Three types of

FAI have been described: the first one is cam type with a morphological changes at the femoral head-neck junction in the form of cam deformity⁹. The second one is pincer type, in which the pathological changes are localized exclusively to the acetabulum as a global (*coxa profunda, protrusio acetabuli*) or local overcoverage (*retroversio acetabuli*) of the femoral head, where the motion of the hip leads to the impact of the femoral neck on the edge of the acetabulum and consequent damage to the acetabular labrum⁴. The third, mixed and the most common type of FAI is the combination of the previous two^{7, 10-13}. Synovitis of the hip is a reaction of the articular synovium on the systemic or local pathological substrate in the form of synovial joint fluid production¹⁴⁻¹⁶ or specific hypertrophic synovium reaction that is seen in pathological conditions such as pigmented villonodular synovitis, tuberculosis or rheumatoid pannus¹⁷⁻²⁰. In the literature we found no case of hypertrophic non-specific synovitis combined with any kind of FAI.

We presented a patient with nonspecific chronic hypertrophic synovitis of the hip, combined with a mixed form of FAI, who was surgically treated.

Case report

A 20-year-old male patient suffered from pain in the left groin, which lasted two years before the surgery. The patient was treated in several orthopedic institutions with non-steroid anti-inflammatory drugs, physiotherapy, skin traction, and suggested total hip replacement. Six months before the sur-

gery, during the ultrasound examination of the hip joint, synovial fluid in the hip was asserted for which injection of corticosteroids into the joint was administered. After that, the symptoms became more pronounced, the patient began to limp visibly, walking on flat surfaces was difficult, and climbing up the stairs was practically impossible. At clinical examination the patient walked with the left leg in external rotation, with highlighted limps on that leg, Trendelenburg sign was positive on the left leg, highlighted weakness of muscles of the thigh and the left gluteal region, active flexion of the hip was possible up to 70°, internal rotation up to 5°, adduction up to 10° in the hip flexion of 70°. Impingement test was positive in the hip flexion of 30–70°³. The patient brought computed tomography (CT) image of the hips and nuclear magnetic resonance (NMR) that were made before the application of corticosteroids into the joint and which showed that the bone and soft tissue structures of the hips were normal. Biochemical and laboratory tests were also within normal limits. Standardized anteroposterior radiography of the hips showed characteristics findings for femoroacetabular impingement reported earlier in literature: (Figure 1) a strong mutual retroversion of the acetabulum 12° on the left and 11° on the right hip²¹, mutual positive sign of ischial spine projection²², the angle α was 46° on the right and 44° on the left²³, acetabular index, mutual 10°²⁴, mutual Wiberg angle 36°²⁵, a Kolodyaphyseal angle of 126° that was asserted bilaterally.

In profile, Dunn-Ripstein-Müller's radiographs of the hips²⁶, the angle α on the left was 64° (normal value of this angle is below 50°), and on the right 42° (Figure 2).

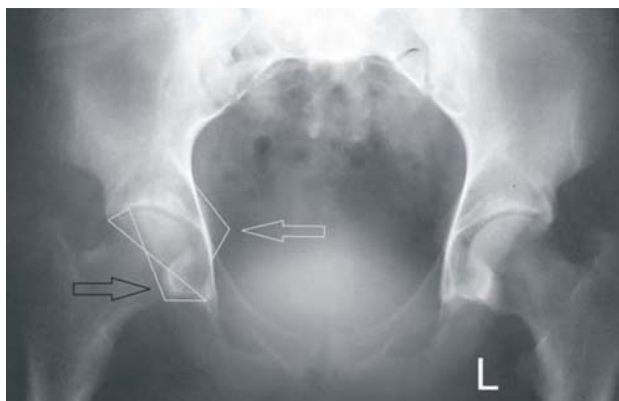


Fig. 1 – Standardized anteroposterior x-ray of the hips showing bilaterally positive sign of the ischial spine (white arrow), and acetabular retroversion (black arrow).

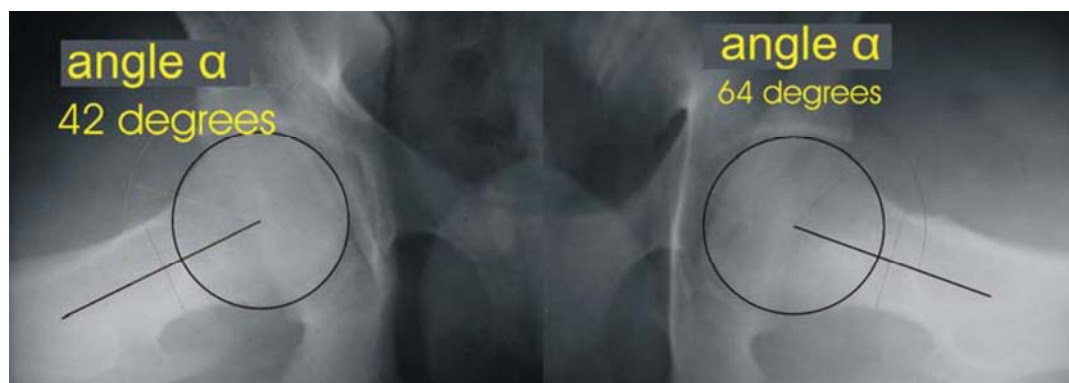


Fig. 2 – Standardized profile Dunn-Rippstein-Müller x-ray images of the hips: the left hip (right picture) – angle α 64°; the right hip (left picture) – angle α 42°.

Such clinical and radiographic findings revealed the existence of mixed-type of FAI on the left hip, due to which we proposed surgical treatment to the patient. The patient was operated on. It was planned to lift the acetabular labrum from its base, to osteotomize overcovered anterior and superior edge of the acetabulum, then, reinsert acetabular labrum in a new slot, and osteotomize cam deformity at the femoral head-neck junction in its antero-superior region. Lateral hip incision and transtrochanteric flip osteotomy of the hip were done²⁷, and after anterior "Z" hip capsulotomy unexpected hypertrophic synovial hip reaction was ascerted (Figure 3).

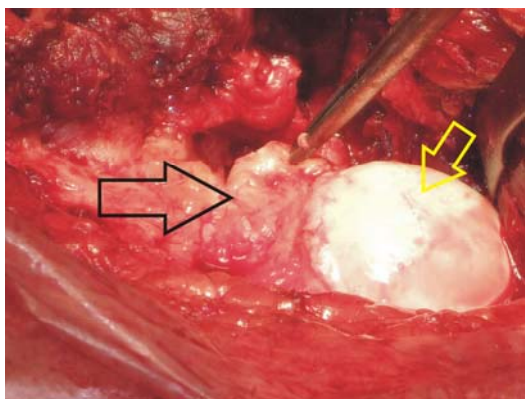


Fig. 3 – Intraoperative image: hypertrophied synovitis of the joint capsule on the anterior and superior femoral neck and head (black arrow), and femoral head (yellow arrow).

Entire extra-acetabular part of the joint was filled with synovial tissue which had fully and seriously damaged the anterior and the superior part of the acetabular labrum. Partial hip synovectomy was performed, tissue samples were sent to histopathological analysis, the damaged parts of the labrum was resected, without possibility to be reinserted, anterior and superior part of the acetabular edge were osteotomized to reduce acetabular retroversion. Osteochondroplasty of the cam prominence at the femoral head-neck junction was done (Figure 4), and thus, intraoperatively, hip flexion of 90° and internal rotation of 30° was obtained²⁸. After joint capsule reconstruction, osteotomized part of the greater trochanter was re-fixed with two cortical screws and the operational wound was closed.

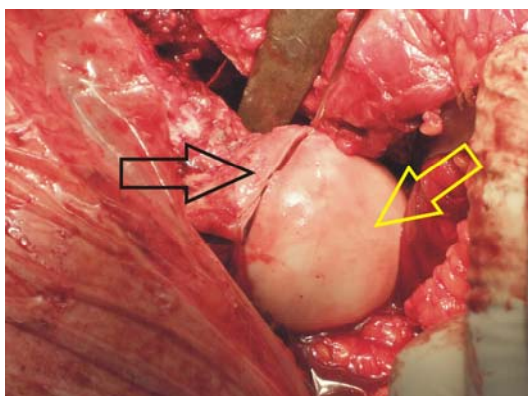


Fig. 4 – Intraoperative picture: osteochondroplasty of the cam deformity of the femoral head-neck junction (black arrow), and femoral head (yellow arrow).

Postoperatively, the patient was reimbursed with 400 mL of blood; low molecular weight heparin thromboprophylaxis

for seven days was introduced, followed by oral anticoagulant therapy for up to six weeks after the surgery. On the first post-operative day active exercises in bed started and walking on the crutches was allowed from the second day with touching the tip of toes of the operated leg for six weeks after the surgery. Histopathological findings confirmed a nonspecific chronic hypertrophic synovitis of the hip. Two years after the surgery, the patient was asymptomatic, without limping on the left leg and with normal life activities. Flexion of the operated hip was 90°, internal rotation 25°, adduction 30°, impingement test was negative. On the anteroposterior radiographs of the hips, the acetabular angle of retroversion was reduced up to 4°, the angle α was 40° and 49° on the profile of Dunn-Rippstein-Müller radiographs of the left hip.

Discussion

Damages of the acetabular labrum cause pain and partial loss of function of the hip in young adults. There is a number of reasons for labrum lesions, such as mechanical trauma of the hip (hip dyslocations, acetabular fractures) and in patients with FAI^{1-7, 10-13}, otherwise, it is the result of biological specific or nonspecific synovial hypertrophic pannus production¹⁷⁻²⁰. Morphological bone changes in the area of the acetabulum and/or proximal femur in patients with FAI reduce physiological distance between these anatomical structures of the hip, lead to premature contact-impact of the femoral neck on the edge of the acetabulum, causing damage of the acetabular labrum and acetabular cartilage adjacent to it, but never lead to mechanical irritation of the articular capsule and its hypertrophic response.

We presented a patient with a clear clinical and radiographic picture of mixed form of FAI with normal biochemical, CT and NMR findings in which the subjective symptoms suddenly worsened after intra-articular application of corticosteroids in the hip joint. We found intraoperatively and verified histologically, a nonspecific reaction of the hypertrophic synovium, an unexplained etiology, that filled the hip joint, further decreasing the space between the edge of the acetabulum and the anterior and superior part of the femoral neck, with additional deterioration of the patient's subjective complaints, hip movements and irreversible damage of the acetabular labrum without the possibility to be reinserted but only partially resected. There were no reports in the literature to compare with our experience. We hypothesized, as a possible explanation, that the intra-articular administration of corticosteroids was the reason for the development of nonspecified hypertrophy of the hip synovium, but it needs further research.

FAI has been, in the last 20 years, well-defined pathological and pathophysiological entity which is treated only surgically^{1-15, 29}.

Conclusion

We believe that young adults with pain in the groin and with normal biochemical, CT and NMR parameters should not be exposed to unnecessary and inappropriate treatment (skin traction, total hip replacement or intra-articular corticosteroid application), but to be appropriately operated on.

R E F E R E N C E S

- Burnett SR, della Rocca GJ, Prather H, Curry M, Maloney WJ, Clohisy JC. Clinical presentation of patients with tears of the acetabular labrum. *J Bone Joint Surg Am* 2006; 88(7): 1448–57.
- Seldes RM, Tan V, Hunt J, Katz M, Winiarsky R, Fitzgerald RH. Anatomy, histologic features, and vascularity of the adult acetabular labrum. *Clin Orthop Relat Res* 2001; 382: 232–40.
- Ganç R, Parviç J, Beck M, Leunig M, Nötçli H, Siebenrock KA. Femoroacetabular impingement: a cause for osteoarthritis of the hip. *Clin Orthop Relat Res* 2003; 417: 112–20.
- Ganç R, Leunig M, Leunig-Ganç KH, Harris W. The Etiology of Osteoarthritis of the Hip, An Integrated Mechanical Concept. *Clin Orthop Relat Res* 2008; 466(2): 264–72.
- Giori NJ, Trousdale RT. Acetabular retroversion is associated with osteoarthritis of the hip. *Clin Orthop Relat Res* 2003; 417: 263–9.
- Laude F, Boyer T, Nogier A. Anterior femoroacetabular impingement. *Joint Bone Spine* 2007; 74(2): 127–32.
- Leunig M, Ganç R. Femoroacetabular impingement: a common cause of hip complaints leading to arthrosis. *Unfallchirurg* 2005; 108(9–10): 12–7. (German)
- Parviç J, Leunig M, Ganç R. Femoroacetabular impingement. *J Am Acad Orthop Surg* 2007; 15(9): 561–70.
- Ito K, Minka MA, Leunig M, Werlen S, Ganç R. Femoroacetabular impingement and the cam-effect. A MRI-based quantitative anatomical study of the femoral head-neck offset. *J Bone Joint Surg Br* 2001; 83(2): 171–6.
- Allen D, Beaulé PE, Ramadan O, Doncette S. Prevalence of associated deformities and hip pain in patients with cam-type femoroacetabular impingement. *J Bone Joint Surg Br* 2009; 91(5): 589–94.
- Beck M, Kalhor M, Leunig M, Ganç R. Hip morphology influences the pattern of damage to the acetabular cartilage: femoroacetabular impingement as a cause of early osteoarthritis of the hip. *J Bone Joint Surg Br* 2005; 87(7): 1012–8.
- Crawford JR, Villar RN. Current concepts in the management of femoroacetabular impingement. *J Bone Joint Surg Br* 2005; 87(11): 1459–62.
- Tanzer M, Noisieux N. Osseous abnormalities and early osteoarthritis: the role of hip impingement. *Clin Orthop Relat Res* 2004; 429: 170–7.
- Vijlbrief AS, Bruijnzeels MA, van der Woude JC, van Suijlekom-Smit LW. Incidence and management of transient synovitis of the hip: a study in Dutch general practice. *Br J Gen Pract* 1992; 42(363): 426–8.
- Romesburg JW, Wasserman PL, Schoppe CH. Metallosis and Metal-Induced Synovitis Following Total Knee Arthroplasty: Review of Radiographic and CT Findings. *J Radiol Case Rep* 2010; 4(9): 7–17.
- Rehman MA, Umer M, Sepah YJ, Wajid MA. Bullet-induced synovitis as a cause of secondary osteoarthritis of the hip joint: a case report and review of the literature. *J Med Case Rep* 2007; 1(1): 171.
- Hans-Joachim A. Pigmented villonodular synovitis of the hip in systemic lupus erythematosus: a case report. *J Med Case Rep* 2011; 5: 443.
- Rajakumar D, Rosenberg AM. Mycobacterium tuberculosis monoarthritis in a child. *Pediatr Rheumatol Online J* 2008; 6(1): 15.
- Schumacher HR, Dorwart BB, Bond J, Alavi A, Miller W. Chronic synovitis with early cartilage destruction in sickle cell disease. *Ann Rheum Dis* 1977; 36(5): 413–9.
- Rhodes LA, Conaghan PG, Radjenovic A, Grainger AJ, Emery P, McGonagle D. Further evidence that a cartilage-pannus junction synovitis predilection is not a specific feature of rheumatoid arthritis. *Ann Rheum Dis* 2005; 64(9): 1347–9.
- Meunier P, Lefevre C, Le SJ, Kerbol B, Riot O, Meriot P, et al. A simple method for measuring anteversion of the acetabulum from a frontal radiograph of the hip. *J Radiol* 1987; 68(12): 799–804. PubMed PMID: 3446815
- Kalberer F, Sierra RJ, Madan SS, Ganç R, Leunig M. Ischial spine projection into the pelvis : a new sign for acetabular retroversion. *Clin Orthop Relat Res* 2008; 466(3): 677–83.
- Nötçli HP, Wyss TF, Stoocklin CH, Schmid MR, Treiber K, Hodler J. The contour of the femoral head-neck junction as a predictor for the risk of anterior impingement. *J Bone Joint Surg Br* 2002; 84(4): 556–60.
- Tönnis D. Normal values of the hip joint for the evaluation of X-rays in children and adults. *Clin Orthop Relat Res* 1976; 119: 39–47.
- Wiberg G. Studies on dysplastic acetabular and congenital subluxation of the hip joint. *Acta Chir Scand* 1939; 83(Suppl 58): 1–135.
- Dunn DM. Anteversion of the neck of the femur; a method of measurement. *J Bone Joint Surg Br* 1952; 34-B(2): 181–6.
- Ganç R, Gill TJ, Gautier E, Ganç K, Krügel N, Berlemann U. Surgical dislocation of the adult hip. A technique with full access to the femoral head and acetabulum without the risk of avascular necrosis. *J Bone Joint Surg* 2001; 83(8): 1119–24.
- Mardones RM, Gonzalez C, Chen Q, Zobitz M, Kaufman KR, Trousdale RT. Surgical treatment of femoroacetabular impingement: evaluation of the effect of the size of the resection. *J Bone Joint Surg Am* 2005; 87(2): 273–9.
- Vukašinović Z, Spasovski D, Živković Z. Femoroacetabular impingement related to Legg-Calvé-Perthes disease. *Srp Arh Celok Lek* 2011; 139(11–12): 834–7. (Serbian)

Received on December 7, 2013.

Accepted on October 15, 2014.

Online First October, 2015.