



## Successful operative treatment of neglected pure Chopart joint dislocation: two case reports and literature review

### Uspešno operativno lečenje previđene čiste luksacije Šopartovog zgloba: prikaz dva slučaja i pregled literature

Draško Vasović\*, Lazar Mičeta\*\*†, Filip Čučaković\*, Aleksandar Jevtić\*\*†,  
Danilo Jeremić\*\*†, Nemanja Slavković\*\*†

\*Institute for Orthopedic Surgery “Banjica”, Belgrade, Serbia; †University of Belgrade,  
Faculty of Medicine, Belgrade, Serbia

#### Abstract

**Introduction.** Chopart joint dislocation (CJD) represents a rare injury that is often initially unrecognized. Because of this, but also because of the increased morbidity it leads to, and due to poor treatment outcomes, this injury represents a significant clinical problem. **Case report.** We present two patients with overlooked CJD admitted to our institution within one year. The first case was a 63-year-old male, who suffered an injury after falling down the stairs, while the second case was a 33-year-old female injured in a traffic accident. Both patients were initially treated under the diagnosis of foot and ankle sprain. Upon their admission and subsequent computed tomography diagnostics, overlooked pure CJD was diagnosed in both patients. They both underwent open reduction and internal fixation of the Chopart joint using K-wires. Six weeks after the surgery, the K-wires were removed, a below-knee orthosis was applied for walking, and partial weight-bearing was allowed with a gradual increase to full weight-bearing over the next six weeks. Physical therapy was initiated. After the six-month follow-up, both patients were successfully rehabilitated, with a final American Orthopaedic Foot and Ankle Society score of 76 out of 100 for the female patient and a score of 84 out of 100 for the male patient. **Conclusion.** Despite the delayed diagnosis and postponed operative treatment, the functional outcomes of pure CJD treated by open reduction and percutaneous K-wiring can be satisfactory. Additional studies are required to gain a better insight into the prevalence and causative factors of the possible complications in such a treatment approach to the mentioned injury.

#### Key words:

joint dislocations; orthopedic procedures; tarsal joints; treatment delay; treatment outcome.

#### Apstrakt

**Uvod.** Dislokacija Šopartovog zgloba (DŠZ) predstavlja retku povredu, inicijalno često neprepoznatu. Najpre zbog toga, ali i zbog povišenog morbiditeta do koga dovodi, kao i zbog loših ishoda lečenja, ta povreda predstavlja značajan klinički problem. **Prikaz bolesnika.** Prikazana su dva slučaja previđene DŠZ kod bolesnika primljenih u našu ustanovu tokom jedne godine. Prvi slučaj je bio muškarac star 63 godine, povređen prilikom pada niz stepenice, dok je drugi slučaj bila žena stara 33 godine, povređena u saobraćajnom udesu. Oba bolesnika su u početku lečena pod dijagnozom distorzije stopala i skočnog zgloba. Po prijemu u ustanovu, nakon sprovedene dijagnostike kompjuterizovanom tomografijom, kod oba bolesnika konstatovano je postojanje previđene čiste DŠZ. Oba bolesnika su hirurški lečena otvorenom repozicijom i unutrašnjom fiksacijom Šopartovog zgloba pomoću K-igala. Šest nedelja nakon operacije, K-igle su uklonjene, primenjena je potkolena ortoza za hodanje, uz dopušten delimičan oslonac na operisanu nogu i sa postepenim povećanjem do punog oslanjanja u narednih šest nedelja. Započeta je fizikalna terapija. Nakon šestomesečnog praćenja, oba bolesnika su bila uspešno rehabilitovana, dostigavši konačni *American Orthopaedic Foot and Ankle Society* skor od 76/100 za bolesnicu i 84/100 za bolesnika. **Zaključak.** Uprkos kasnom postavljanju dijagnoze i odloženom operativnom lečenju, funkcionalni ishodi bolesnika sa čistim DŠZ, lečenih otvorenom repozicijom i perkutanom fiksacijom pomoću K-igala, mogu biti zadovoljavajući. Potrebne su dodatne studije da bi se stekao bolji uvid u prevalenciju i uzročne faktore mogućih komplikacija ovakvog pristupa lečenju navedene povrede.

#### Ključne reči:

zglob, iščašenja; ortopedske procedure; tarzalni zglob; lečenje, odlaganje; lečenje, ishod.

## Introduction

The Chopart joint (CJ), composed of the talonavicular and calcaneal-cuboidal joints, plays a crucial role in foot mechanics and stability. According to Ponkilainen et al.<sup>1</sup>, CJ dislocations (CJD) are rare injuries that account for 18.2% of midfoot traumas (56 out of 307) or 5.9% of foot and ankle injuries (out of a total of 953) shown using computed tomography (CT) scan analysis during the 5-year period. Neglected CJD are rare but pose significant challenges in diagnosis and management<sup>2</sup>. CJD typically result from high-energy trauma and can involve the entire Chopart complex or isolated joints within it. Prompt reduction and restoration of anatomical alignment are essential for successful outcomes, but literature shows that up to 41% of these injuries are unrecognized on the first patient-doctor encounter<sup>3</sup>. Due to this reason, such injury poses a significant clinical problem, leading to increased morbidity and poor treatment outcomes.

Nonoperative treatment is possible in some cases by performing closed reduction and cast immobilization, but in many acute cases, closed reduction is unsuccessful<sup>4</sup>. In chronic dislocations, there is no place for closed reduction, and surgical treatment is necessary. Surgical treatment aims to reconstruct the talonavicular joint and address associated fractures (if they exist), while fusion may be considered for severe calcaneal-cuboidal joint damage or in unsuccessful reduction of the joint<sup>4,5</sup>. Operative management is focused on joint alignment and congruence restoration, which are essential for favorable outcomes.

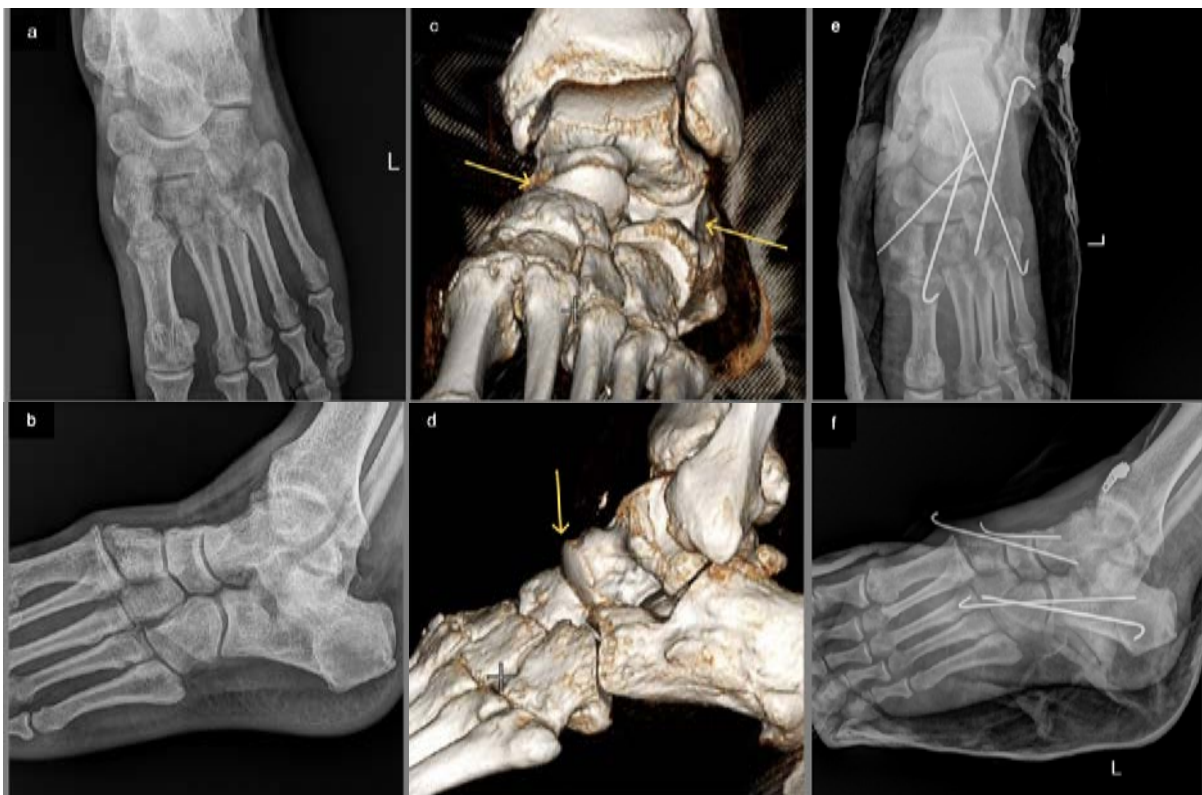
This paper presents two cases of neglected CJD treated surgically and followed by favorable medium-term outcomes.

## Case reports

### Case 1

A 63-year-old male sustained an injury from falling down the stairs. Initially evaluated at a regional trauma center, he was diagnosed with a left ankle sprain. Treatment consisted of bandaging, non-steroidal anti-inflammatory medications, and rest. While pain and discomfort during weight-bearing decreased after the first week of the treatment, they persisted at a lower level afterward. The patient was examined at our institution eight weeks after the injury, presenting a visible midfoot deformity with an altered shape of the medial arch.

Imaging diagnostics were performed, and although the initial biplanar X-rays did not show definitive radiological signs of an injury (Figure 1 a, b), subsequent computed tomography (CT) diagnostics revealed a CJD (Figure 1 c, d). The patient underwent surgical treatment involving an open reduction of the CJ and transfixion using four K-wires (Figure 1 e, f). Postoperatively, the patient was immobilized with a below-knee orthosis for six weeks without weight-bearing. After the removal of the K-wires, physical therapy commenced, gradually progressing from partial



**Fig. 1 – Imaging diagnostics of Case 1 patient: plain X-rays did not show definitive radiological signs of injury (a, b); three-dimensional computed tomography showed dislocation in the Chopart joint (yellow arrows) (c, d); postoperative X-rays, with transfixion of talonavicular and calcaneocuboid joints, show the congruence of these joints (white lines indicate K-wires) (e, f).**

weight-bearing with the orthosis to full weight-bearing at twelve weeks after surgery (Figure 2 a, b).

The patient returned to normal daily activities without pain or deformity. During the follow-up period of eighteen months, the patient achieved an American Orthopaedic Foot and Ankle Society (AOFAS) score of 84 out of 100.

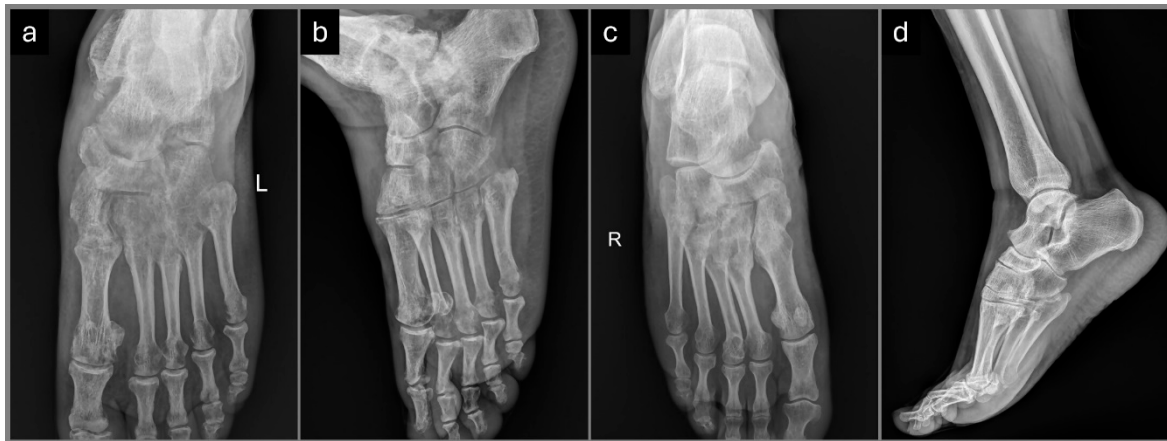
#### Case 2

A 33-year-old female was injured in a traffic accident. Initially managed according to the trauma protocol at a large emergency center, she received a diagnosis of a right ankle sprain without any other major injuries. Initially, there were no significant symptoms apart from diffuse ankle-foot pain.

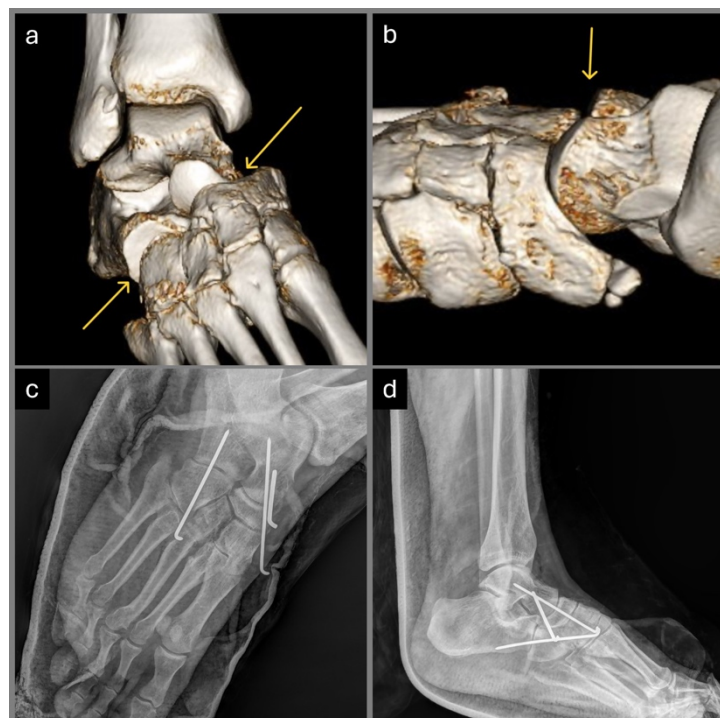
Due to prolonged pain, the patient presented to our institution ten months after the initial trauma.

Follow-up X-rays of the foot did not confirm clear radiological signs of injury. However, subsequent CT scans revealed a Chopart dislocation of the right foot (Figure 3 a, b). Similar to Case 1, surgical treatment involved an open reduction of the CJ and transfixion using four K-wires (Figure 3 c, d), followed by an identical postoperative protocol (Figure 2 c, d).

The final follow-up of this patient was conducted two years after surgery. The patient exhibited no deformity and reported no pain but experienced a reduction in foot movement, resulting in an AOFAS score of 76 out of 100.



**Fig. 2 – X-rays at the end of follow-up: in both cases, Case 1 (a, b) and Case 2 (c, d), the normal foot anatomy with congruent Chopart joint was confirmed.**



**Fig. 3 – Imaging diagnostics of Case 2 patient: three-dimensional computed tomography shows plantar dislocation of the Chopart joint (yellow arrows) (a, b); postoperative X-rays (white lines indicate K-wires) (c, d).**

## Discussion

The CJ complex, comprised of the talonavicular and calcaneocuboid joints, represents a low-mobile but essential anatomical construct that enables proper mechanics of the foot. It is critical to normal gait and weight-bearing and is intrinsically involved in the movements of inversion and eversion<sup>6,7</sup>. The normal function of the CJ requires strong ligamentous support. Ligaments stabilizing the joint include the dorsal talonavicular ligament, bifurcate ligament, dorsal calcaneocuboid ligament, short and long plantar ligaments, and spring ligament<sup>8</sup>.

Trauma in this region may cause fractures and/or dislocations. Chopart dislocations include both pure-dislocations (exclusively capsulo-ligament injuries) and fracture-dislocations, being mainly caused by motor vehicle accidents and fall from height<sup>3,9</sup>. Main and Jowett<sup>10</sup> classified these injuries into the following five types according to the direction of the deforming force and the resulting displacement: medial, longitudinal, lateral, plantar, and crush. The frequency is by far the highest for the medial and plantar dislocations<sup>3,9,10</sup>.

Purely transligamentous dislocations are quite rare (4%) and generally missed or misdiagnosed. The reason for misdiagnosis, in addition to the low prevalence, could be the lack of familiarity with the entity and the absence of obvious radiological signs on standard radiographs (anteroposterior, lateral, and 45° oblique projections). The CJ appears as a harmonic double wave (“lazy S-shape”), the so-called “cyma line”, when viewed laterally. Incongruity at the CJ needs to be suspected if this line is disrupted. Furthermore, stress radiographs with forced abduction and adduction carried out under sufficient local anesthesia can be useful<sup>11</sup>.

Many authors suggest CT scanning because it allows reconstructive modeling to determine the presence and degree of the dislocation. Delays in diagnosis are common and may adversely affect the long-term prognosis, with the potential for developing instability, foot deformity, and eventual osteoarthritis of the CJ<sup>2</sup>.

So far, no consensus has been made on the treatment choice of Chopart pure dislocations (CPD). Different procedures are imposed as a method of selection, and they imply closed reduction with or without percutaneous fixation, open reduction with or without internal fixation, and primary fusion of CJ.

Restoring the proper length of the medial and lateral columns, as well as the proper alignment of the foot axes, are the primary objectives of the treatment. Compared to closed reduction before internal fixation, initial open reduction with internal fixation generates noticeably better results for CPD<sup>9</sup>. According to Richter et al.<sup>9</sup>, 43% of pure dislocations need internal fixation after closed reduction. The authors concluded that maintaining the anatomical integrity of a pure dislocation is necessary so that closed reduction can be successfully treated. Furthermore, repeated attempts at closed reduction often result in more damage to the soft tissues<sup>12</sup>.

Rammelt and Missbach<sup>11</sup> found over a 10-year follow-up that open reduction and internal fixation (with K-wires)

generate better results than closed reduction and percutaneous fixation. However, the pure dislocations had the worst prognosis. Generally, K-wire (1.6–2.0 mm) fixation allows adequate joint congruence and ligamentous healing<sup>13</sup>.

Contaminated or infected soft tissues, advanced peripheral vascular disease, chronic venous insufficiency with skin ulceration, poor patient compliance, diabetic neuro-osteoarthropathy (Charcot foot), evident immunodeficiency, and a critical state of the patient’s overall health are all contraindications to a formal open reduction<sup>13</sup>. Primary fusion of the CJ should be reserved for cases of severe instability and destruction of the articular surface because of the pivotal role of these joints in global foot function<sup>14</sup>.

Although CJ injuries are rare, complications of such injuries are common. Metcalfe et al.<sup>2</sup> analyzed 10 cases with follow-up between six and 76 months, and results indicated that 50% of them had significant long-term complications. Complications of nonoperative treatment included deformity, instability, and posttraumatic arthritis. The most frequent operative complications were wound healing problems and nerve injuries. Wound healing complications are related to operative timing (too early) and technique (presence of undermining wound edges and flaps after suturing the surgical wound). In this context, early operative timing refers to the condition of the soft tissues. High-energy injuries often result in extensive soft tissue damage, characterized by significant swelling, hematomas, and the formation of skin blisters. Performing surgery too early, before the soft tissue damage has sufficiently stabilized, can compromise wound healing, as the tissues may not yet be capable of tolerating the stress of surgical intervention. Peroneal and sural nerve injury can be caused by inadequate surgical approach or aggressive retraction. Other complications like deep venous thrombosis, compartment syndrome, and complex regional pain syndrome (especially after initially overlooked Chopart injuries) have been rarely reported<sup>2,3,9,13-15</sup>. It should be emphasized that intraoperative relative shortening of the medial column leads to *cavus* deformity, whereas relative shortening of the lateral column leads to a posttraumatic flatfoot<sup>12</sup>.

Both of our CPD cases were successfully treated with open reduction and K-wire transfixation without postoperative complications. After the physical rehabilitation, both patients had a satisfactory AOFAS score result and did not indicate the existence of any clinically significant complaints. After six months of follow-up, radiographic images indicated a maintained congruence and anatomical position of the CJ. Only two cases were presented here. However, considering that there is no data in the literature about the protocol and recommendations for the treatment of CPD patients who were not timely diagnosed, these cases can serve as an incentive for some future research.

## Conclusion

Despite the delayed diagnosis and postponed operative treatment, the functional outcomes of pure Chopart dislocation treated by open reduction and percutaneous K-wiring can be satisfactory. Additional studies are required for a better insight into the prevalence and causative factors of the possible complications in such treatment.

## R E F E R E N C E S

1. *Ponkilainen VT, Laine HJ, Mäenpää HM, Mattila VM, Haapasalo HH.* Incidence and Characteristics of Midfoot Injuries. *Foot Ankle Int* 2019; 40(1): 105–12.
2. *Metcalfe TSN, Aamir J, Mason LW.* Chopart dislocations: a review of diagnosis, treatment and outcomes. *Arch Orthop Trauma Surg* 2024; 144(1): 131–47.
3. *Van Dorp KB, de Vries MR, van der Elst M, Schepers T.* Chopart joint injury: a study of outcome and morbidity. *J Foot Ankle Surg* 2010; 49(6): 541–5.
4. *Viegas G.* Midtarsal joint dislocations: acute and chronic management with review of the literature and case presentation. *The Foot* 2000; 10(4): 198–206.
5. *Klaue K.* Chopart fractures. *Injury* 2004; 35 Suppl 2: SB64–70.
6. *Elftman H.* The transverse tarsal joint and its control. *Clin Orthop* 1960; 16: 41–6.
7. *Blackwood CB, Yuen TJ, Sangeorzan BJ, Ledoux WR.* The midtarsal joint locking mechanism. *Foot Ankle Int* 2005; 26(12): 1074–80.
8. *Walter WR, Hirschmann A, Alaia EF, Tafur M, Rosenberg ZS.* Normal anatomy and traumatic injury of the midtarsal (chopart) joint complex: An imaging primer. *Radiographics* 2019; 39(1): 136–52.
9. *Richter M, Thermann H, Huefner T, Schmidt U, Goesling T, Krettek C.* Chopart joint fracture-dislocation: initial open reduction provides better outcome than closed reduction. *Foot Ankle Int* 2004; 25(5): 340–8.
10. *Main BJ, Jowett RL.* Injuries of the midtarsal joint. *J Bone Joint Surg Br* 1975; 57(1): 89–97.
11. *Rammelt S, Missbach T.* Chopart joint injuries: Assessment, treatment, and 10-year results. *J Orthop Trauma* 2023; 37(1): e14–21.
12. *Honeycutt MW, Perry MD.* The Chopart variant dislocation: Plantar dislocation of the cuboid and navicular. *Foot Ankle Orthop* 2019; 4(3): 2473011419876262.
13. *Rammelt S, Schepers T.* Chopart injuries: When to fix and when to fuse? *Foot Ankle Clin* 2017; 22(1): 163–80.
14. *Rammelt S.* Chopart and Lisfranc Fracture-Dislocations. In: *Bentley G*, editor. *European Surgical Orthopaedics and Traumatology*. Berlin, Heidelberg: Springer; 2014. p. 3835–57.
15. *Kotter A, Wieberneit J, Braun W, Rüter A.* The Chopart dislocation: results of a frequently underestimated injury and its sequelae. A clinical study. *Unfallchirurg* 1997; 100(9): 737–41. (German)

Received on February 6, 2024

Revised on November 8, 2024

Revised on December 10, 2024

Revised on December 26, 2024

Accepted on January 15, 2025

Online First March 2025