



## The Fisher Grade in predicting a degree of cerebral vasospasm in patients after intracranial aneurysm rupture

Fišerova klasifikacija u predviđanju nastanka cerebralnog vazospazma kod bolesnika nakon rupture intrakranijalne aneurizme

Djula Djilvesi, Tomislav Cigić, Vladimir Papić, Igor Horvat, Mladen Karan,  
Petar Vuleković

Clinic of Neurosurgery, Clinical Center of Vojvodina, Novi Sad, Serbia

### Abstract

**Background/Aim.** Intracranial aneurysms are pathological enlargement of the wall of cerebral arteries. Intracranial aneurysms rupture is a dramatic event with a significant morbidity and mortality. The Fisher Grade is widely accepted in assessment of the extensiveness of aneurysmal subarachnoid hemorrhage (aSAH) and the presence of other intracranial hemorrhage on the computed tomography (CT) scan. Significant early complication of aSAH may be a cerebral vasospasm. The aim of this study was to determine the relationship between the extensiveness of aSAH, assessed by the Fisher Grade on admission, with the intensity of cerebral vasospasm in patients with ruptured intracranial aneurysm. **Methods.** This prospective clinical study included 50 patients with aSAH hospitalized at the Clinic of Neurosurgery, Clinical Center of Vojvodina, Novi Sad, Serbia. All the patients underwent 256-layer cranial CT and CT angiography on admission and on the day 9. Based on native CT scans, they were classified according to the Fisher Grade. On CT angiography images, intensity of cerebral vasospasm was determined. **Results.** On the basis of admission CT images, 24% of patients were classified into the Fisher Grade group 2, while 34% and 42% were in the groups 3 and 4, respectively. A positive correlation of the Fisher Grade on admission with the intensity of cerebral vasospasm was established, but with no statistical significance ( $q = 0.273$ ,  $p = 0.160$ ). **Conclusion.** This study showed that the Fisher Grade is not significant in predicting the intensity of cerebral vasospasm in patients hospitalized with intracranial aneurysm rupture.

### Key words:

intracranial aneurysm; subarachnoid hemorrhage; cerebral arteries; vasospasm, intracranial; disease progression; severity of illness index; tomography, x-ray computed; angiography; predictive value of tests.

### Apstrakt

**Uvod/Cilj.** Intrakranijalne aneurizme su patološka proširenja zida moždanih arterijskih krvnih sudova. Ruptura intrakranijalnih aneurizmi je dramatičan događaj sa značajnim morbiditetom i mortalitetom. Za procenu opsežnosti subarahnoidalne hemoragije aneurizmatičke etiologije (aneurizmatička subarahnoidalna hemoragija aSAH) i prisustva drugih intrakranijalnih hemoragija na nalazu kompjuterizovane tomografije (CT) široko je prihvaćena Fišerova klasifikacija. Značajna rana komplikacija aSAH je cerebralni vazospazam. Cilj rada bio je da se utvrdi korelacija obima aSAH vrednovanog Fišerovim stepenom na prijemu sa intenzitetom cerebralnog vazospazma kod bolesnika sa rupturiranom intrakranijalnom aneurizmom. **Metode.** Ovo prospektivno kliničko istraživanje, obuhvatilo je 50 bolesnika sa aSAH lečenih na Klinici za neurohirurgiju Kliničkog centra Vojvodine. Kod svih bolesnika je na prijemu i najčešće 9. dana od prijema, urađen CT i CT angiografski pregled glave na 256-slojnom CT aparatu. Na osnovu nativnih CT pregleda izvršena je klasifikacija po Fišerovoj skali. Na CT angiografskim pregledima određivan je intenzitet cerebralnog vazospazma. **Rezultati.** Na osnovu CT nalaza na prijemu, 24% bolesnika klasifikovano je u grupu 2 po Fišerovoj skali, 34% bolesnika u grupu 3, i 42% bolesnika u grupu 4. Utvrđena je pozitivna korelacija Fišerove skale na prijemu sa intenzitetom vazospazma, ali ta korelacija nije bila statistički značajna ( $q = 0,273$ ,  $p = 0,160$ ). **Zaključak.** Ova studija je pokazala da Fišerova klasifikacija na prijemu bolesnika nakon rupture intrakranijalne aneurizme nije statistički značajna za predviđanje intenziteta cerebralnog vazospazma.

### Ključne reči:

aneurizma, intrakranijalna; krvarenje, subarahnoidno; aa. cerebri; vazospazam, intrakranijalni; bolest, progresija; bolest, indeks težine; tomografija, kompjuterizovana, rendgenska; angiografija; testovi, prognostička vrednost.

## Introduction

Intracranial aneurysms (IA) are pathological enlargements of the wall of intracranial arteries. IA rupture and consequent bleeding in the subarachnoid, intraventricular or subdural space is a dramatic event with significant morbidity and mortality. Most studies show that the incidence of aneurysmal subarachnoid hemorrhage (aSAH) is 10–11 cases *per* 100,000 population *per* year, except in China where it is 2 and in Japan and Finland 16.8 to 18.33<sup>1</sup>. Sudden intense headache that does not respond to painkillers occurs in about 80% of patients with aSAH. Symptoms that also indicate aSAH are nausea, vomiting, disturbance of consciousness, meningism, and focal neurological deficit<sup>2</sup>.

The diagnosis of ruptured IA is made by anamnesis, physical, neurological and radiographic examination. Cranial computed tomography (CT) is the best diagnostic tool for the detection of intracranial hemorrhage, hydrocephalus and cerebral infarction. The Fisher Grade is widely accepted in the classification of the extensiveness of the aSAH and the presence of other intracranial hemorrhage on CT images<sup>3</sup>: Fisher Grade 1 – no SAH visualized; Fisher Grade 2 – thin layer of SAH, less than 1 mm thick; Fisher Grade 3 – focal or diffuse layer of SAH, greater than 3 mm in thickness; Fisher Grade 4 – intracerebral or intraventricular clots with or without SAH.

Complications after aneurysm rupture may be early and late. Early complications include aneurysm re-ruptures, hydrocephalus and cerebral vasospasm (CV), while the late ones include general medical complications, late hydrocephalus and epilepsy.

CV is a pathologic, reversible narrowing of the cerebral arteries, which develops a few days after SAH. Symptomatic vasospasm presents narrowing of the arteries of the brain, which results in cerebral ischemia with associated clinical symptoms and signs.

Based on the intensity, CV is classified into mild (0–33%), moderate (34–66%) and severe (67–100%)<sup>4</sup>.

CV involves intracerebral part of cerebral arteries. The distribution and degree of vasospasm correlates with the location and size of aSAH. Delayed onset and relative ability to predict CV offers a chance to act in a therapeutic window that is still narrow. Determining the precise mechanism of vasospasm remains an objective to enable a complete pharmacological preventive treatment<sup>5</sup>.

The incidence of vasospasm after SAH is about 60%, with data from the literature ranging from 20% to 97% as a result of unequal criteria for determination of vasospasm<sup>6</sup>.

There is a proven correlation between the quantity and location of subarachnoid blood with the risk of occurrence and distribution of angiographic vasospasm. If the initial CT scans show a significant amount of SAH (Fisher Grade III), a significant vasospasm develops in 60% of patients. Latest multivariate studies have shown that only the presence of blood in the subarachnoid space is a significant factor for the occurrence of vasospasm<sup>7</sup>.

The aim of this study was to determine the relationship between the extensiveness of aSAH, determined by the Fisher Grade on admission, with the intensity of CV in patients with ruptured IA.

## Methods

This prospective clinical study included a total of 50 patients hospitalized at the, Clinic of Neurosurgery, Clinical Center of Vojvodina Novi Sad, Serbia, due to aSAH. On admission, all patients underwent cranial CT and CT angiography (CTA) with 256-layer “dual energy” CT (Siemens) by the special protocol. All images were processed and reviewed on a workstation “Syngo.via” Siemens.

Initially, a native cranial CT scan was made. Scans were performed from the level of the foramen magnum to the top of the vertex with axial sections at 5 mm and subsequent reconstruction on 1mm. Acquisition parameters were 120 kVA, EffmAs to 320 mA, collimation 0.6 and a matrix of at least 512 × 512 pixels. Native CT examinations were analyzed with triplanar reconstruction in a standard window for brain parenchyma 80 WW and 40 WL. Based on CT images the radiologist determined the extensiveness of SAH and the presence of other intracranial hemorrhages and classified patients according to the Fisher Grade.

CTA of cerebral vessels were performed on admission and on the day 9 or 10 of hospitalization. Two patients underwent CTA on the day 5 and 8, respectively, due to worsening of neurological condition. CTA was performed by scanning in the same given range as native CT, using non-ionic, isoosmolar, iodine contrast (Iohexol, Omnipaque 350, GE Healthcare). The contrast was injected mechanically by “two-headed” Optivanatage DH injector, 1–1.5 mL *per* kg of body weight. Axial cross-section at the level of the Circle of Willis was recorded after 10 s delay from the beginning of the application and then successively, every two seconds, until the appearance of contrast in the internal carotid artery and Circle of Willis, when the scanning was initiated.

CTA images were analyzed with triplanar reconstruction in “angio window”, 700 WW and 80 WL, maximum intensity projection (MIP) reconstruction of axial, coronal and sagittal sections, “Volume rendering” reconstructions, as well as with software application “syngo CT vascular analysis” to determine the diameter of a blood vessel. Before measuring a blood vessel, every single analyzed artery was labeled automatically and set aside in a separate window on the screen, where possible, with additional tools to improve image and determine accurately the appropriate position for the measurement. Then, the automatic determination of the boundaries of the vessel was checked and, if necessary, corrections were made (minimum and maximum Hounsfield units – HU values).

On CTA scans on admission and control CTA scans, seven segments of the proximal blood vessels of the brain in their distal parts were measured: suprasellar parts of internal carotid artery; M1 segments of the middle cerebral artery, A1 segments of the anterior cerebral artery; A2 segments of the anterior cerebral artery; P1 segment of the posterior cerebral artery; vertebral arteries and basilar arteries. If there were evident signs of vasospasm in the distal circulation (M2 and M3), these data were noted and taken into statistical analysis.

The presence of CV was determined on the measured values of arterial narrowing of blood vessels. The presence

of CV was classified into: present (degree of narrowing of blood vessels 5–100%, taking into account the possibility of error in the measurement), and absent (0–5%). Narrowing of the arteries on CTA images were classified into: mild (5–33%), moderate (34–66%) and severe (67–100%).

## Results

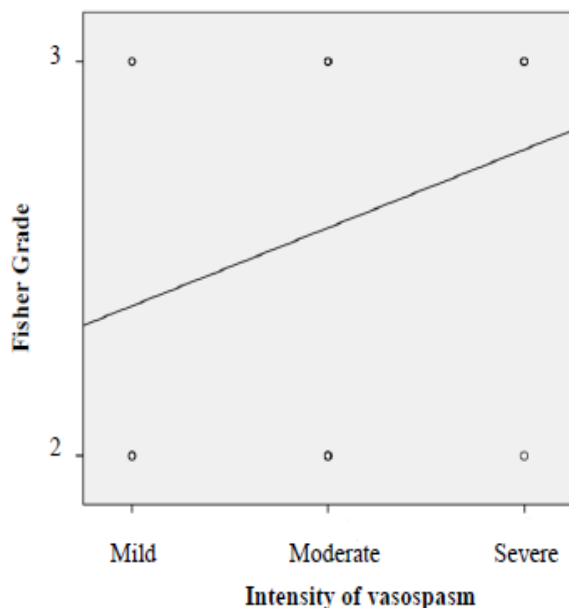
On the basis of CT findings at admission, 24% of the patients were classified as the Fisher Grade 2, 34% of the patients as the Fisher Grade 3 and 42% of the patients as the Fisher Grade 4. On control CTA scans, mild degree of CV was detected in 36% of the patients, moderate in 46% and severe in 9% of the patients.

In the Fisher Grade 2 group, a significant (severe) vasospasm was observed in 7.5% of the patients. In the Fisher Grade 3 group, 29.4% of the patients had a significant vasospasm. This shows a clear correlation, indicating that there are notably more patients with significant vasospasm in the Fisher Grade 3 group, than in the Fisher Grade 2 group (Table 1).

**Table 1**  
**Comparison of the Fishers Grade at admission with the intensity of cerebral vasospasm (CV)**

Fisher Grade	Intensity of CV (% of patients)		
	Mild	Moderate	Severe
2	30	62.5	7.5
3	17.6	52.9	29.4
4	52.4	33.3	14.3

A positive correlation with no statistical significance of the Fisher Grade at admission with the intensity of vasospasm in the whole study group of 50 patients is shown in Figure 1 ( $\rho = 0.273$ ,  $p = 0.160$ ).



**Fig. 1 – Correlation between the Fisher Grade at admission with the intensity of cerebral vasospasm.**

## Discussion

The Fisher Grade was established in 1980 with the assumption that it is valid enough to predict the level of CV after aSAH. This assumption was confirmed by the small sample size (41 patients) in 1983<sup>8</sup>. However, recently in the larger, 2005 series, it has been found that this correlation exists, but it is not significant<sup>9</sup>.

In this study, we determined a positive, but not significant correlation between the Fisher Grade and the intensity of vasospasm.

The Fisher Grade was created in the age when the resolution of imaging technology was about ten times lower than today. Descriptions of the amount of blood in the subarachnoid space in scans from those years could not be considered valid. The biggest difference is in the description of the thickness of SAH less than 1 mm, because in today's CT images that thick collection of SAH is almost always visible. One of the shortcomings of the Fischer Grade is that not all forms of intracranial hemorrhage after IA rupture are defined and classified. The classification of patients with small focal SAH and intracerebral hemorrhage (ICH)/intraventricular hemorrhage (IVH) is unclear, because the Fisher Grade 4 includes only patients with diffuse layer of SAH or without SAH and ICH/IVH. Also, it is not clear into which group to classify patients with SAH and subdural hematoma. Analyzing the admission CT findings in this study, 24% of the patients were classified in the Fisher Grade 2, 34% of the patients in the Fisher Grade 3 and 42% of patients in the Fisher Grade 4. The patients with ICH and the IVC, regardless the amount of SAH, were classified into the Fisher Grade 4.

Angiographic vasospasm was defined as narrowing of the contrast in the main cerebral arteries, which is usually focal, but may be diffuse, as well<sup>10</sup>. A large number of studies have classified the CV as mild (0–30%); moderate (30–50%) and severe or significant (above 50% narrowing of cerebral arteries)<sup>11, 12</sup>. The degree of CV in this study was classified into mild (0–33%), moderate (34–66%) and severe (67–100%), according to the 2008 study of Macdonald et al.<sup>4</sup>. After that study, most studies accepted the new classification. Frequently, it is stated that angiographic vasospasm develops in approximately 67% of patients with aSAH, which is characterized by a higher degree than the mild one<sup>13</sup>. Based on CTA findings, this study determined a mild degree of CV in 36% of the patients, moderate in 46% and severe of CV in 9% of the patients. In our study, 55% of the patients had moderate or severe (significant) CV.

Due to the lack of statistical correlation between the Fisher Grade and the intensity of CV, the modified Fisher Grade was proposed in 2006, which correlates significantly with the intensity of vasospasm and classifies logically the cerebral hemorrhage on CT findings (Table 2)<sup>14</sup>.

The disadvantage of this classification, and probably the reason why the modified Fisher Grade is not widely accepted in neurosurgical clinical practice, is because it is complex and difficult to remember.

**Table 2**  
**Classification of aneurysmal subarachnoid hemorrhage (SAH) on**  
**cranial computed tomography (CT) scans by the modified Fisher Grade<sup>14</sup>**

CT finding	Intraventricular hemorrhage	Modified Fisher Grade
Thick diffuse SAH	present	4
	absent	3
Thick focal SAH	present	4
	absent	3
Thin diffuse SAH	present	2
	absent	1
Thin focal SAH	present	2
	absent	1
No signs of SAH	present	2
	absent	0

### Conclusion

This study points out the advantages and disadvantages of the original classification by Fisher. The Fisher Grade is in a positive, statistically nonsignificant correlation with the degree of cerebral vasospasm, but it is widely accepted and used

in neurosurgical practice. The modified Fischer Grade is in a significant correlation with the intensity of vasospasm, but it is more complex and therefore much less applicable. In the future, it would be desirable to modify both Fisher Grades and combine them into one simple, but accurate classification.

### REFERENCES

1. *Sekhar LN, Heros RC.* Origin, growth, and rupture of saccular aneurysms: a review. *Neurosurgery* 1981; 8(2): 248–60.
2. *Weir B.* Aneurysms affecting the nervous system. Baltimore, MD: Williams & Wilkins; 1987.
3. *Fisher CM, Kistler JP, Davis JM.* Relation of cerebral vasospasm to subarachnoid hemorrhage visualized by computerized tomographic scanning. *Neurosurgery* 1980; 6(1): 1–9.
4. *Macdonald RL, Kassell NF, Mayer S, Raefenacht D, Schmiedek P, Weidauer S,* et al. Clazosentan to overcome neurological ischemia and infarction occurring after subarachnoid hemorrhage (CONSCIOUS-1): randomized, double-blind, placebo-controlled phase 2 dose-finding trial. *Stroke* 2008; 39(11): 3015–21.
5. *Findlay MJ.* Cerebral vasospasm. In: *Win RH,* editor. *Youmans neurologic surgery.* Philadelphia: Saunders; 2004. p. 1840.
6. *Dorsch NW, King MT.* A review of cerebral vasospasm in aneurysmal subarachnoid haemorrhage Part I: Incidence and effects. *J Clin Neurosci* 1994; 1(1): 19–26.
7. *Hatiboglu MA, Bikmaz K, Iplikcioglu AC, Turgut N.* Evaluating the factors affecting cerebral vasospasm in patients after aneurysmal subarachnoid haemorrhage. *Acta Neurochir Suppl* 2008; 104: 363–655.
8. *Kistler JP, Crowell RM, Davis KR, Heros R, Ojemann RG, Zervas T,* et al. The relation of cerebral vasospasm to the extent and location of subarachnoid blood visualized by CT scan: a prospective study. *Neurology* 1983; 33(4): 424–36.
9. *Smith ML, Abrahams JM, Chandela S, Smith MJ, Hurst RW, Le Roux PD.* Subarachnoid hemorrhage on computed tomography scanning and the development of cerebral vasospasm: the Fisher grade revisited. *Surg Neurol* 2005; 63(3): 229–34; discussion 234–5.
10. *Kassell NF, Sasaki T, Colohan AR, Nazar G.* Cerebral vasospasm following aneurysmal subarachnoid hemorrhage. *Stroke* 1985; 16(4): 562–72.
11. *Ferguson SD, Rosen DS, Bardo D, Macdonald RL.* Arterial diameters on catheter and computed tomographic angiography. *World Neurosurg* 2010; 73(3): 165–73; discussion e25.
12. *Ionita CC, Graffagnino C, Alexander MJ, Zaidat OO.* The value of CT angiography and transcranial doppler sonography in triaging suspected cerebral vasospasm in SAH prior to endovascular therapy. *Neurocrit Care* 2008; 9(1): 8–12.
13. *Loch Macdonald R.* Management of cerebral vasospasm. *Neurosurg Rev* 2006; 29(3): 179–93.
14. *Frontera JA, Claassen J, Schmidt JM, Wartenberg KE, Temes R, Connolly ES Jr,* et al. Prediction of symptomatic vasospasm after subarachnoid hemorrhage: the modified fisher scale. *Neurosurgery* 2006; 59(1): 21–7.

Received on September 27, 2014.

Accepted on March 4, 2015.

Online First February, 2016.