



Relationship between IL-1 β production and endodontic status of human periapical lesions

Povezanost stvaranja IL-1 β i karakteristika humanih periapikalnih lezija

Lidija Popovska*, Cena Dimova[†], Biljana Evrosimoska[‡], Vera Stojanovska*,
Ilijana Muratovska*, Bojana Cetenović[§], Dejan Marković[§]

Ss Cyril and Methodius University, Faculty of Dentistry, *Department of Restorative Dentistry and Endodontics, [‡]Department of Oral Surgery, Skopje, Macedonia; University „Goce Delčev“, Faculty of Medical Sciences, [†]Department of Oral and Maxillofacial Surgery and Dental Implantology, Štip, Macedonia; University of Belgrade, Faculty of Dental Medicine, [§]Clinic for Pediatric and Preventive Dentistry, Belgrade, Serbia

Abstract

Background/Aim. Apical periodontitis is mainly caused by bacterial infection within the root canal and periapical bone destruction which are prominent features of this lesion. The aim of this study was to determine the quantity of interleukin-1 β in the tissues of periapical lesions and to analyze its relationships with: lesion size, previous treatments and pathohistological finding of involved teeth. **Methods.** Periapical tissues were obtained from patients undergoing periapical surgery. Out of all 80 cases included in the study, 24 had no previous endodontic treatment (open lesions), 37 were with endodontic failure (closed lesion) and in 15 cases root canal retreatment was performed few months before the surgery. By excluding four samples, the total of 76 samples, consisted of periapical lesions and the apical part of the tooth root, was collected. Each periapical tissue sample was divided into two equal parts. The one half of each lesion was used for quantification of interleukin-1 β in tissue homogenates by the enzyme-linked immunosorbent assay (ELISA) method. The other part of each lesion was used for histopathological evaluation. **Results.** For each of the tissue homogenates, the quantity of interleukin-1 β was measured, and it ranged from 0.6 pg/mg up to 74 pg/mg. There was no significant difference between the symptomatology and amount of interleukin-1 β . Statistical data analysis showed a moderate correlation between lesion size and interleukin-1 β measured values. The highest levels of interleukin-1 β corresponded with chronic lesions in the stages of acute exacerbation and granulomas in early developing stages. Persistent granulomas, scar tissues, non-inflamed cysts and teeth with recently finished endodontic treatments showed a significantly lower level of interleukin-1 β . **Conclusion.** The study results suggest that the differences in quantity of interleukin-1 β correlate to lesion progression and phases of development.

Key words:

periapical periodontitis; interleukin-1 α ; interleukin-1 β ; disease progression.

Apstrakt

Uvod/Cilj. Periapikalni periodontitis najčešće je prouzrokovan bakterijskom infekcijom unetom putem kanala zubnog korena i periapikalnom destrukcijom kosti koje predstavlja glavno obeležje ovih lezija. Cilj ovog istraživanja bio je da se odredi količina interleukina-1 β u uzorcima periapikalnih lezija i da se analizira njihova povezanost sa: veličinom lezija, postojanjem prethodnih endodontskih tretmana i patohistološkim nalazima. **Metode.** Ispitivani su uzorci periapikalnih lezija sakupljeni tokom periapikalnih operativnih intervencija. Od svih 80 bolesnika uključenih u studiju, 24 su pripadali bolesnicima koji nisu podvrgnuti endodontskom tretmanu pre apikotomije (otvorene lezije), 37 su tretirani kao endodontski neuspesh (zatvorene lezije), a kod 15 bolesnika endodontski retreatman je sproveden nekoliko meseci pre oralno-hirurške intervencije; četiri uzorka su isključena iz studije. Svaki uzorak koji se sastojao od periapikalne lezije i vrha korena zuba podeljen je na dva jednaka dela. Prva polovina svakog uzorka korišćena je za kvantifikaciju interleukina-1 β u tkivnom homogenatu metodom *enzyme-linked immunosorbent assay* (ELISA). Druga polovina uzorka korišćena je za histopatološku analizu. **Rezultati.** U svakom tkivnom homogenatu izmerena je količina interleukina-1 β , čije vrednosti su se kretale od 0,6 do 74 pg/mg. Naši rezultati nisu potvrdili značajnu razliku između simptomatomičnih i asimptomatomičnih slučajeva; dokazano je prisustvo umerene korelacije između veličine lezija i vrednosti interleukina-1 β . Najviše vrednosti interleukina-1 β potvrđene su u fazama akutnog pogoršanja hroničnih lezija i kod granuloma u ranim razvojnim fazama. Kod starih granuloma, ožiljačnih tkiva, zuba sa nedavno završenim endodontskim retreatmanom i neinflamiranih cista, vrednosti interleukina-1 β bile su značajno niže. **Zaključak.** Rezultati istraživanja pokazuju da su razlike u količini interleukina-1 β u korelaciji sa progresijom lezija i fazama njihovog razvoja.

Ključne reči:

periodontitis, periapikalni; interleukin-1 α ; interleukin-1 β ; bolest, progresija.

Introduction

Apical periodontitis is mainly caused by bacterial infection within the root canal and periapical bone destruction which are prominent features of this lesion^{1,2}. One of the main signs of periapical lesion is bone resorption³. The impact of apical periodontitis on the general health can be observed from two aspects: as an unwanted and harmful effect from the response of the organism, and on the other hand, as a positive bone tissue reaction by creating tampon zone around the process and releasing the defense constituents⁴. Bone resorption serves as a main indicator through which the phases of propagation of periapical lesion can be followed up. Contrary, the radiological signs of bone apposition may be used in assessment of the effectiveness of non-surgical endodontic treatment of periapical lesion⁵.

Many biologically active molecules such as: prostaglandins, lipopolysaccharide (LPS) complex, bacterial endotoxins and inflammatory cytokines: interleukin-1 alpha (IL-1 α), interleukin-1 beta (IL-1 β), tumor necrosis factor-alpha (TNF- α), tumor necrosis factor-beta (TNF- β), interleukin-6 (IL-6) and interleukin-11 (IL-11) have been shown to possess the capacity to activate bone resorption⁶. These molecules were previously referred as osteoclast-activated factors⁶.

The crucial elements in the proinflammatory cascade, IL-1 and TNF- α are activated as a response to an infection or immunologic insults⁶. Interleukin-1 (IL-1) can be found in two forms: IL-1 α and IL-1 β . Although both forms have similar biological activities, it is believed that IL-1 β is much more efficient in stimulating bone resorption and has a role in functions of a broader spectrum⁷. Apart from the stimulation of bone resorption, IL-1 β also hinders bone formation^{8,9}. This is a very important fact when the resorption is already manifested as persistent chronic periapical lesion, because continually low level of cytokine production by the inflammatory cells may be insufficient to trigger additional bone resorption, and further on to prevent the formation of reparative bone tissue^{8,9}.

However, IL-1 β has been shown to be the most potent stimulus of bone resorption⁶. A variety of cells possess the capacity to produce IL-1 β including: fibroblasts, endothelial cells, B-cells and macrophages, representing its major source⁶. IL-1 β has been detected in gingival tissue of patients with periodontitis^{10,11}, in gingival crevicular fluid after application of orthodontic forces¹², in periradicular lesions, contrary to non-inflamed pulpal tissues¹³. IL-1 β is the prevailing form of IL-1 found in human periapical lesions and their exudates¹⁴⁻¹⁶. It is believed that IL-1 stimulates the proliferation of fibroblasts and induces the formation of granuloma¹⁷.

The aim of this study was to determine quantity of IL-1 β in the tissues of periapical lesions, and knowing that its local production demonstrates the activity of human periapical periodontitis, to further analyze its relationship with: lesion size, previous treatments and pathohistological findings of selected teeth.

Methods

Eighty patients of both sexes, aged from 18 to 55 (38 \pm 12) years, with diagnosed persistence of periapical le-

sions, were selected for this study. They were in good general health and seven days prior to examination did not receive any antibiotic therapy. The patients have been asked for anamnestic data, clinical examinations were performed, as well as radiographic analysis. Radiographs were used to evaluate quality of previous endodontic treatments. The assessment of radiographic size of the periapical lesion was performed by measuring two maximum diameters of radiotransparent zone with a caliper (accuracy of 0.05 mm), and expressed in mm². The study was approved by the local Ethics Committee (No 09-1849/2).

During clinical examination the special attention was given to the presence of subjective symptoms: pain, and/or objective symptoms such as sensitivity to percussion or palpation, present swelling and possible drainage through the sinus tract. Based on clinical data and history of the disease, lesions were categorized either as asymptomatic or symptomatic lesions.

According to endodontic status, the teeth were divided into four study groups: 1) the group I: 25 samples of periapical lesions obtained from teeth with infected root canals communicating with the oral cavity; 2) the group IIa: 25 samples of periapical lesions obtained from teeth with obviously unsuccessfully endodontic treatment at least two years prior to examination with failure; 3) the group IIb: 15 samples of periapical lesions obtained from teeth with persisting process during a period of two years after endodontic treatment, although, based on radiographic examination the endodontic treatment was successful; 4) the group III: 15 samples of periapical lesions obtained from teeth after the biomechanical root canal instrumentation which lasted for three months and proceed with the final obturation.

For further investigation, in the course of oral surgery procedures, 80 tissue samples were obtained. Periapical tissues samples were collected from patients undergoing periapical surgery at the Department of Oral Surgery at the Faculty of Dentistry in Skopje. The sample consisted of the periapical lesion tissue and apical part of the tooth root. Each periapical tissue sample was divided into two equal parts.

One half of each lesion was used for quantification of IL-1 β in tissue samples. The samples were embedded in 0.5 mL neutral buffer with added protease-inhibitors and preservatives (PBS, pH = 7.2). Each piece was frozen and stored at -70 °C. The concentrations of IL-1 β were determined using the enzyme-linked immunosorbent assay (ELISA) method (h-Interleukin-1 ELISA, Roche Molecular Biochemicals, Switzerland), according to the manufacturer's instructions. The detection limit of IL-1 β was 2 pg/mL.

The other part of each lesion was immediately fixed in 10% formalin; paraffin sections were stained with haematoxylin-eosin and processed for histopathologic analysis using light microscopy (Leitz dialux 20, Ernst Leitz Wetzlar). Based on the histopathological evaluation, stages of granulomas were classified as follows: early (presence of numerous capillary blood vessels embedded in edematous connective tissue infiltrated with a variety of inflammatory cells), mature (chronic granulation tissue distributed in four zones around the apex of the tooth), late (high amount of col-

lagen deposits with increased number of fibrocytes and reduced inflammatory infiltrate) and recovering (visible precipitated collagen with significantly reduced cellularity and scattered macrophages and plasma cells infiltrate). Periapical chronic diffuse inflammation implied chronically inflamed granulation tissue with the absence of fibrous tissue and diffuse infiltration of the surrounding tissue. Healthy pulp tissue from five impacted third molars served as a negative control.

The data were analyzed using SPSS/Win programs (version 17.0). Kolmogorov-Smirnov test and Shapiro-Wilk's W test were used to identify the distribution of variables. All data were expressed in mean values ± standard deviations ($\bar{x} \pm SD$) and percentage. The correlations between the observed parameters were detected using the Pearson correlation and Wilcoxon Rank Sum W test. The significant differences among the groups were tested using Student *t*-test, χ^2 test and Median Test. The difference in the testing was considered significant at the level of $p < 0.05$.

Results

The procedure of determining IL-1β in the tissue homogenates was successfully performed on 76 samples (it was impossible to determine IL-1β in four cases due to the insuf-

ficient quantity of tissue that was at disposal). Its quantity varied from very low values up to 74 pg/mg of protein. No IL-1β was detected in control pulp tissue samples.

Concentrations of IL-1β in the samples correlated with the size of lesion, clinical symptoms, previous endodontic status and confirmed histological findings. Table 1 presents the relationship between the size of the lesions and concentration of IL-1β in the samples. There was a tendency of smaller lesions to contain a lower quantity of IL-1β, but still smaller lesions with high quantity of IL-1β and large lesions with a minimal amount of the IL-1β were detected.

Linear correlation was determined between the measured values of IL-1β and the size of the lesions, by applying the Pearson's correlation test (Figure 1). The examined relationship between these values demonstrated moderate positive correlation ($r = 0.22$; $p < 0.05$).

The quantity of IL-1β in periapical lesions with respect to the examined groups is presented in Figure 2. It can be noticed that the values of IL-1β of closed lesions (IIa and IIb group) were higher compared to the group I, likewise the III group (cases of recently completed therapy). However, the analysis performed concerning the quantity of IL-1β, showed that there were no significant differences among the investigated groups (Median Test; $p = 0.239$). The differences

Table 1
Relationship between interleukin-1 beta (IL-1β) production and radiographic size of the lesions

IL-1β (pg/mL)	Radiographic size of lesions (mm ²)				Total n (%)
	small (< 4.99) n (%)	medium (5–14.99) n (%)	large (15–25) n (%)	extra large (> 25) n (%)	
< 2.99	3 (37.5)	11 (28.2)	3 (18.75)	1 (7.7)	18 (23.7)
3–5.99	1 (12.5)	10 (25.6)	7 (43.75)	4 (30.8)	22 (28.9)
6–8.99	1 (12.5)	3 (7.7)	4 (25)	2 (15.5)	10 (13.2)
9–11.99	0 (0)	4 (10.1)	0 (0)	0 (0)	4 (5.3)
12–15.99	3 (37.5)	5 (13.0)	0 (0)	1 (7.7)	9 (11.8)
15–17.99	0 (0)	3 (7.7)	0 (0)	0 (0)	3 (3.9)
> 18	0 (0)	3 (7.7)	2 (12.5)	5 (38.5)	10 (13.2)
Total	8	39	16	13	76

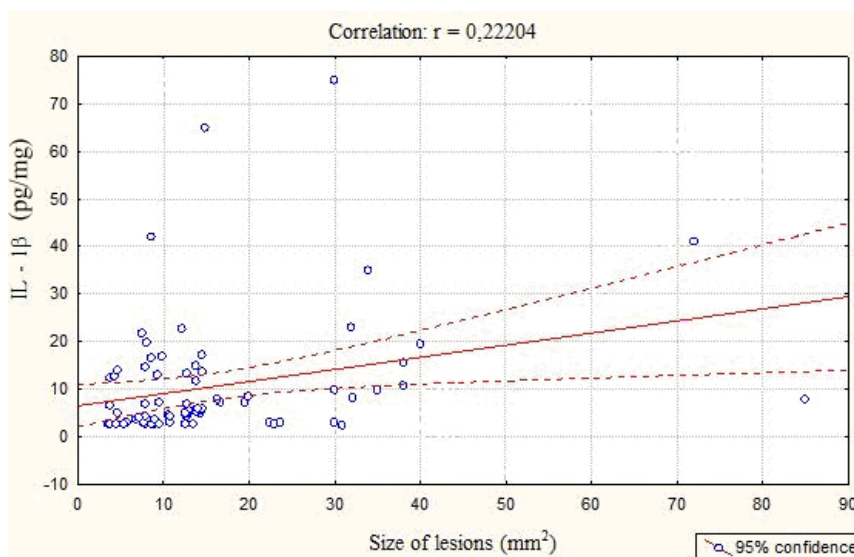


Fig. 1 – The correlation between the sizes of the periapical lesions and the quantity of interleukin-1β (IL-1β).

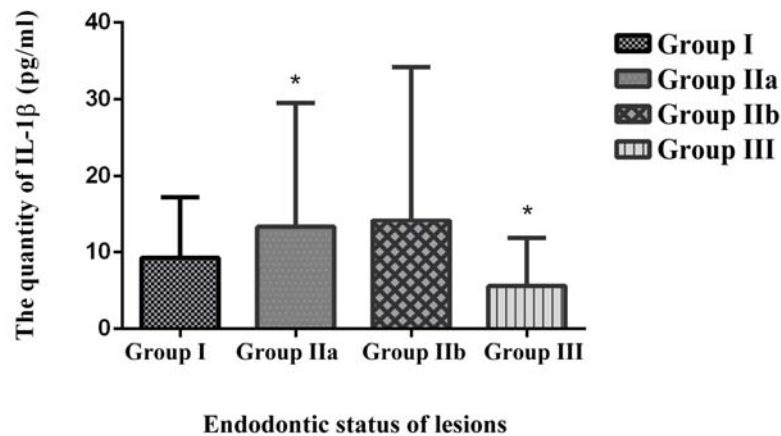


Fig. 2 – The quantity of interleukin-1 beta (IL-1β) in periapical lesions

[Asterisks indicate statistically significant difference among investigated groups ($p < 0.05$)]

group I – lesions obtained from teeth with infected root canals communicating with the oral cavity; group IIa – lesions obtained from teeth with obviously unsuccessfully endodontic treatment at least two years prior to examination with failure; group IIb – lesions obtained from teeth with persisting process during a period of two years after endodontic treatment, although, based on radiographic examination the endodontic treatment was successful; group III – lesions obtained from teeth after the biomechanical root canal instrumentation which lasted for three months and proceed with the final obturation.

between all the groups (comparing each group with all the others) were analyzed using the Student *t*-test.

Symptomatic lesions were the most frequent (52%) in the group I. In the group II cases with symptomatic and asymptomatic lesions were approximately equal. In the group III, the most cases were asymptomatic (93.3%). Kruskal-Wallis analysis showed significant differences among the investigated groups ($\chi^2 = 14.4$; $p = 0.0024$).

The correlation between the symptomaticity of the lesion with the quantity of IL-1β was examined by Wilcoxon's Rank Sum *W* test which proved that there were no significant differences between the existence of the symptoms and the quantity of IL-1β in the samples ($W = 1,601$; $p = 0,0666$).

The differences between the quantities of IL-1β in samples with different pathohistological diagnosis are shown in Table 2. The highest values of IL-1β were detected in early granulomas, while the quantity of IL-1β amounted 21.48 pg/mg, followed by 19.06 pg/mg, for the cysts. The lowest quantities of IL-1β were detected in late granulomas, scars and recovering granulomas. The analysis with the χ^2 -test po-

inted to the fact that there was a very high significant difference between the pathohistological diagnosis and the quantity of IL-1β ($\chi^2 = 34,185$; $p = 0.000$).

Furthermore, the analyses of IL-1β among the groups significantly differed. The analysis performed by the *t*-test showed that there were statistically significant differences in the noted values of IL-1β between: the diffuse inflammation and mature granuloma ($p = 0.0021$), the early and mature granuloma ($p = 0.000$), abscess and the cyst ($p = 0.0175$), as well between the abscess and mature granuloma ($p = 0.0004$). No significant differences were confirmed in the quantity of IL-1β between: the diffuse inflammation and early granuloma, the diffuse inflammation and abscess, or between the cysts and mature granuloma ($p > 0.05$).

Discussion

Considering the fact that the local production of IL-1β in human periapical lesions reflects the activity of the disease¹⁸ was the crucial reason for conducting this investigation.

Table 2

The quantity of interleukin-1 beta (IL-1β) in lesions with different histopathological manifestation

Histopathological manifestation	n	IL-1β (pg/mg), $\bar{x} \pm SD$
Diffuse inflammation	7	12.43 ± 6.60
Granuloma		
early	9	21.48 ± 13.50
mature	25	4.90 ± 4.40
late	7	3.84 ± 2.34
recovering	4	2.36 ± 1.20
Scar	4	1.82 ± 1.02
Abscess	13	6.48 ± 4.80
Cyst	11	19.06 ± 16.91

\bar{x} – mean value; SD – standard deviation.

In addition, IL-1 β level in the samples may reflect disease severity¹⁸, opposite to transforming growth factor- β ¹⁹.

The ratio between the size of the lesion and the quantity of IL-1 β showed a moderate positive correlation in our study ($p < 0.05$), meaning that higher quantities of IL-1 β were detected in bigger lesions. However, smaller lesions containing large quantities of IL-1 β and large lesions with barely measurable quantities of IL-1 β were also detected. It remains unresolved whether there is another factor which could have possible influence on this ratio. In Fouad's²⁰ research, the number of cells containing IL-1 β were proportional to the size of the lesion. Higher levels of IL-1 β and endotoxin contents were also related to the larger size of the radiolucent area²¹.

The distribution of IL-1 β in the samples belonging to the groups with the different endodontic status showed that closed lesions (groups IIa and IIb) had highest measured values, especially in cases where the endodontic treatment was unsuccessful. These values were lower regarding the open lesions. The most logical explanation concerning this result could lay in the possible natural drainage in these clinical cases. Matsuo et al.¹⁶ examined the quantity of IL-1 β in the periapical exudates during the endodontic treatment and showed that there was a possibility of its decreasing by the drainage through the root canal.

The decreasing tendency of IL-1 β values was observed following the treatment of chronic inflammation, endodontic treatment of root canal¹⁶, or periodontal treatment²². This finding supports our results, showing the lowest values of IL-1 β in the group with recent endodontic treatments. These results are also in accordance with those of Tavares et al.²³.

Symptomatology did not have significant effect on the quantity of IL-1 β in the lesion, although there was a tendency to isolate a higher quantity of IL-1 β in the samples obtained from the symptomatic cases. Lim et al.¹⁵ and Matsuo et al.¹⁶ showed the same results, i.e. these authors could not find any significant difference between levels IL-1 β in the samples of periapical lesions with different clinical findings. The different results were published by Gazivoda et al.²⁴ and Jakovljevic et al.²⁵, demonstrating that IL-1 β levels were significantly higher in specimens obtained from symptomatic lesions compared to asymptomatic ones.

It has been known that the diffuse chronic inflammation belongs to the group of active forms of periapical lesions with significant activity of the granulation tissue²⁶. On the other hand, it is proved that the macrophages are predominant immunocompetent cells during the development of the early granulomas²⁷. The early granuloma is characterized by increased cellularity and presence of higher number of monocytes and groups of foamy macrophages²⁷. Since these

cells are the most productive source of interleukins, increasing quantity of IL-1 β was expected result. In late granulomas, the number of macrophages decline, as does, in fact, the total number of inflammatory cells²⁷. Wang and Stashenko¹⁷ clearly showed that even in the non-inflamed tissue around the apex, the minimal resorption could be observed. This is probably the reason why a certain minimal quantity of IL-1 β was detected, even in scars, as shown in our study (1.82 pg/mg).

The results of Jakovljevic et al.²⁵ showed that the concentration of IL-1 β was significantly higher in radicular cysts compared to periapical granulomas. These results are not in accordance with the results of our study, meaning that higher content of IL-1 β was registered especially in early granulomas, but not in cysts which had a slightly higher content of IL-1 β compared to granulomas. Possible explanation for acquiring such results could be that the cysts included in our investigation were in a relatively asymptomatic phase with very little chronic infiltration into their walls. The literature is not abound with such data, and only few studies have compared the levels of pro-inflammatory cytokines between periapical granulomas and radicular cysts²⁸⁻³⁰. According to Hoening et al.²⁸, human radicular cystic tissue contained between 0.823 pg/mg and 18.026 pg/mg of IL-1 β . These authors concluded that these findings may be extremely relevant in cystic growth and episodes of alveolar bone resorption around the cystic lesion²⁸. Also, according to the results of Meghji et al.²⁹ IL-1 β was only found in the samples of inflammatory radicular cysts. Except two abscesses in our study sample, which were typically chronic, all the others were phoenix-abscesses with recent exacerbations. In the course of these exacerbations a change in the cell populations is expected to occur, involving massive infiltration of polymorphonuclears and lymphocytes, which are clearly separated from the rest of the tissues³⁰. Johannessen et al.³¹ have shown that macrophage during exacerbations often form major aggregates near the apex, unlike their diffuse placement in chronic lesions.

Conclusion

The highest levels of IL-1 β corresponded to chronic lesions in the stages of acute exacerbation and granulomas in early developing stages. Persistent granulomas, scar tissues, non-inflamed cysts and teeth with recently completed endodontic treatments showed a significantly lower levels of IL-1 β . The study results suggest that the differences in quantity in IL-1 β may be an indicator for lesion progression and its phases of development.

R E F E R E N C E S

1. Sundqvist G. Ecology of the root canal flora. *J Endod* 1992; 18(9): 427-30.
2. Peculiene V, Maneliene R, Balikonyte E, Drukteinis S, Rutkunas V. Microorganisms in root canal infections: A review. *Stomatologija* 2008; 10(1): 4-9.
3. Laux M, Abbott PV, Pajarola G, Nair PN. Apical inflammatory root resorption: A correlative radiographic and histological assessment. *Int Endod J* 2000; 33(6): 483-93.
4. Stashenko P. Role of immune cytokines in the pathogenesis of periapical lesions. *Endod Dent Traumatol* 1990; 6(3): 89-96.

5. *Cetenović B, Marković D, Petrović B, Perić T, Jokanović V.* Use of mineral trioxide aggregate in the treatment of traumatized teeth in children: Two case reports. *Vojnosanit Pregl* 2013; 70(8): 781–4.
6. *Dinarelo CA.* Interleukin-1. *Cytokine Growth Factor Rev* 1997; 8(4): 253–65.
7. *Hamachi T, Anan H, Akamine A, Fujise O, Maeda K.* Detection of interleukin-1 beta mRNA in rat periapical lesions. *J Endod* 1995; 21(3): 118–21.
8. *Stasbenko P, Denbirst FE, Peros WJ, Kent RL, Ago JM.* Synergistic interactions between interleukin 1, tumor necrosis factor, and lymphotoxin in bone resorption. *J Immunol* 1987; 138(5): 1464–8.
9. *Matsumoto A, Anan H, Maeda K.* An immunohistochemical study of the behavior of cells expressing interleukin-1 alpha and interleukin-1 beta within experimentally induced periapical lesions in rats. *J Endod* 1998; 24(12): 811–6.
10. *Birkedal-Hansen H.* Role of cytokines and inflammatory mediators in tissue destruction. *J Periodont Res* 1993; 28(6 Pt 2): 500–10.
11. *Offenbacher S.* Periodontal diseases: pathogenesis. *Ann Periodontol* 1996; 1(1): 821–78.
12. *Kapoor P, Kharbanda OP, Monga N, Miglani R, Kapila S.* Effect of orthodontic forces on cytokine and receptor levels in gingival crevicular fluid: A systematic review. *Prog Orthod* 2014; 15(1): 65.
13. *Stasbenko P, Wang CY, Tani-Isbii N, Yu SM.* Pathogenesis of induced rat periapical lesions. *Oral Surg Oral Med Oral Pathol* 1994; 78(4): 494–502.
14. *Barkhordar RA, Hussain MZ, Hayashi C.* Detection of interleukin-1 beta in human periapical lesions. *Oral Surg Oral Med Oral Pathol* 1992; 73(3): 334–6.
15. *Lim GC, Torabinejad M, Kettering J, Linkhardt TA, Finkelman RD.* Interleukin 1-beta in symptomatic and asymptomatic human periradicular lesions. *J Endod* 1994; 20(5): 225–7.
16. *Matsuo T, Ebisu S, Nakanishi T, Yonemura K, Harada Y, Okada H.* Interleukin-1 alpha and interleukin-1 beta periapical exudates of infected root canals: Correlations with the clinical findings of the involved teeth. *J Endod* 1994; 20(9): 432–5.
17. *Wang CY, Stasbenko P.* Characterization of bone-resorbing activity in human periapical lesions. *J Endod* 1993; 19(3): 107–11.
18. *Kuo ML, Lamster IB, Hasselgren G.* Host mediators in endodontic exudates. I. Indicators of inflammation and humoral immunity. *J Endod* 1998; 24(9): 598–603.
19. *Lukic A.* Transforming growth factor- β is a major down-regulatory cytokine in periapical lesions. *Balk J Stom* 2000; 4(3): 157–60.
20. *Fouad AF.* IL-1 alpha and TNF-alpha expression in early periapical lesions of normal and immunodeficient mice. *J Dent Res* 1997; 76(9): 1548–54.
21. *Martinho FC, Chiesa WM, Leite FR, Cirelli JA, Gomes BP.* Correlation between clinical/radiographic features and inflammatory cytokine networks produced by macrophages stimulated with endodontic content. *J Endod* 2012; 38(6): 740–5.
22. *Oh H, Hirano J, Takai H, Ogata Y.* Effects of initial periodontal therapy on interleukin-1 β level in gingival crevicular fluid and clinical periodontal parameters. *J Oral Sci* 2015; 57(2): 67–71.
23. *Tavares WL, Brito LC, Henriques LC, Teles FR, Teles RP, Vieira LQ, et al.* Effects of calcium hydroxide on cytokine expression in endodontic infections. *J Endod* 2012; 38(10): 1368–71.
24. *Gazivoda D, Džopalić T, Božić B, Tatomirović Z, Brkić Z, Colić M.* Production of proinflammatory and immunoregulatory cytokines by inflammatory cells from periapical lesions in culture. *J Oral Pathol Med* 2009; 38(7): 605–11.
25. *Jakovljević A, Knežević A, Karalić D, Soldatović I, Popović B, Milasin J, et al.* Pro-inflammatory cytokine levels in human apical periodontitis: Correlation with clinical and histological findings. *Aust Endod J* 2015; 41(2): 72–7.
26. *Kawashima N, Okiji T, Kosaka T, Suda H.* Kinetics of macrophages and lymphoid cells during the development of experimentally induced periapical lesions in rat molars: A quantitative immunohistochemical study. *J Endod* 1996; 22(6): 311–6.
27. *Metzger Z.* Macrophages in periapical lesions. *Endod Dent Traumatol* 2000; 16(1): 1–8.
28. *Hoening JF, Rordorf-Adam C, Siegmund C, Erard F.* Measurement of interleukin 1 alpha and 1 beta (IL-1 alpha and IL-1 beta) in human cystic lesions of the jaw. Implications for the pathogenesis of radicular cysts. *Bull Group Int Rech Sci Stomatol Odontol* 1991; 34(2): 67–72.
29. *Meghji S, Qureshi W, Henderson B, Harris M.* The role of endotoxin and cytokines in the pathogenesis of odontogenic cysts. *Arch Oral Biol* 1996; 41(6): 523–31.
30. *Lukic A, Arsenijević N, Vujančić G, Ramić Z.* Quantitative analysis of the immunocompetent cells in periapical granuloma: Correlation with the histological characteristics of the lesions. *J Endod* 1990; 16(3): 119–22.
31. *Johannessen AC, Nilsen R, Skaug N.* Enzyme histochemical characterization of mononuclear cells in human dental periapical chronic inflammatory lesions. *Scand J Dent Res* 1984; 92(4): 325–33.

Received on December 28, 2015.

Revised on March 10, 2016.

Accepted on March 22, 2016.

Online First October, 2016.